

Official Organ of the European  
Society of Gastrointestinal  
Endoscopy (ESGE)  
and affiliated societies

# Endoscopy

## Editor-In-Chief

T. Rösch, Germany

## Co-Editors

M. Bretthauer, Norway  
M. Dinis-Ribeiro, Portugal  
A. May, Germany  
T. Ponchon, France  
N. Vakil, USA  
K. Yasuda, Japan

## Advisory Board

M. Classen, Germany  
J. Geenen, USA  
G. A. Lehman, USA  
N. Soehendra, Germany  
H. Suzuki, Japan  
G. Tytgat, The Netherlands  
C. Williams, UK

## Former Editors

M. Classen, Germany  
L. Demling, Germany

## Publishers

### Georg Thieme Verlag KG

Ruedigerstraße 14  
D-70469 Stuttgart  
P.O. Box 30 11 20  
70451 Stuttgart  
Germany

### Thieme Medical Publishers, Inc.

333 Seventh Avenue  
USA, New York, NY 10001

For subscription information  
please contact: [endoscopy@thieme.de](mailto:endoscopy@thieme.de)

## Reprint

Volume 44 · 2012

© Georg Thieme Verlag KG

Reprint with the permission  
of the publishers only

# Transesophageal pulmonary lobectomy with single transthoracic port assistance: study with survival assessment in a porcine model

## Authors

J. Moreira-Pinto<sup>1,3</sup>, A. Ferreira<sup>1,2,4</sup>, A. Miranda<sup>1,2</sup>, C. Rolanda<sup>1,2,4</sup>, J. Correia-Pinto<sup>1,2,5</sup>

## Institutions

Institutions are listed at the end of article.

**submitted** 12. July 2011  
**accepted after revision**  
15. November 2011

## Bibliography

**DOI** <http://dx.doi.org/10.1055/s-0031-1291594>  
Endoscopy 2012; 44: 354–361  
© Georg Thieme Verlag KG  
Stuttgart · New York  
ISSN 0013-726X

## Corresponding author

**J. Correia-Pinto, MD, PhD**  
Instituto de Ciências da Vida e Saúde (ICVS)  
Escola de Ciências da Saúde;  
Universidade do Minho  
Campus de Gualtar  
4709-057 Braga  
Portugal  
Fax: +351-253-604831  
jcp@ecsau.de.uminho.pt

**Background and study aims:** Thoracoscopic pulmonary lobectomy is being performed in an increasing number of patients. The aims of the current study were to assess natural orifice transluminal endoscopic surgery (NOTES) as an alternative to transthoracic endoscopic surgery, and to test the feasibility of peroral transesophageal right upper pulmonary lobectomy with the assistance of a single transthoracic trocar.

**Methods:** In 10 acute and 4 survival pigs, right upper pulmonary lobectomy was performed using a forward-viewing double-channel gastroscope and an operative thoracoscope with a 5-mm working channel inserted through a single transthoracic 12-mm port. Time, safety, and feasibility of the following steps were recorded in all animals: esophagotomy, hilar dissection, individual ligation of the hilum elements, pulmonary lobectomy, and specimen retrieval. In the survival experiments, esophagotomy was closed using a reticulated laparoscopy suture device and an esophageal stent was placed. These animals were kept alive and monitored for 2 weeks.

**Results:** Esophagotomy was performed safely in all animals (mean procedure duration  $5.4 \pm 1.7$  minutes). Dissection of the right upper lobe hilum elements (bronchus, arteries, and veins) was carried out without adverse events. Individual ligation of the hilum elements was performed in all but two cases (time for dissection and ligation  $44.2 \pm 14.8$  minutes). Lobectomy and specimen retrieval were completed in all animals ( $9.5 \pm 3.1$  minutes). Esophagotomy closure and stent placement were carried out in  $20.0 \pm 2.8$  minutes in the survival animals. These animals fed normally and gained weight postoperatively without signs of disease. Endoscopic examination before necropsy revealed a pseudo-diverticulum in one animal, and wound dehiscence with confined collection/recess in the remaining animals.

**Conclusions:** Transesophageal right upper pulmonary lobectomy using single transthoracic trocar assistance is feasible and may represent a step towards scar-free pulmonary lobectomy.

## Introduction

In natural orifice transluminal endoscopic surgery (NOTES), new approaches to the thorax are emerging as alternatives to the classic transthoracic endoscopic surgery. In 2007, Sumiyama et al. proposed transesophageal access to the thoracic cavity [1]. Since then, transvesical-transdiaphragmatic thoracoscopy [2], transgastric-transdiaphragmatic thoracoscopy [3], and transtracheal thoracoscopy [4] have also been suggested. The transesophageal approach has been considered preferable as a direct entry to the thorax and posterior mediastinum for several simple thoracic procedures in porcine models [5–11]. However, the transesophageal approach is typically considered to be highly risky because of possible mechanical abrasion and trauma sustained

by surrounding structures. Moreover, an ineffective esophagotomy closure can be devastating, resulting in serious infectious complications. In fact, some of the recognized difficulties of NOTES procedures, such as safe port creation, infection prevention, tissue manipulation, and suturing and anastomosis establishment, seem to be particularly relevant in the transesophageal approach. In view of this, Rolanda et al. recently proposed the combination of single transthoracic trocar assistance with transesophageal NOTES in order to increase the safety and feasibility of more complex procedures [12].

Video-assisted thoracoscopic surgery (VATS) was first described in the early 1990s. Initial applications included chest exploration, pleural effusion or pneumothorax management, and limited resection of lung nodules [13–16]. As minimally in-

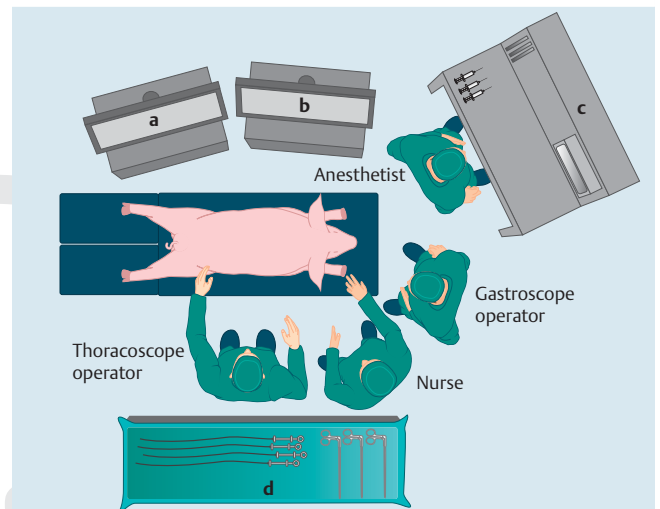
vasive techniques improved, clinical application of VATS became progressively widespread for more complex procedures. Through this technique, VATS lobectomy became feasible and safe even for oncologic resection [17–22]. The endoscopic approach allows meticulous hemostasis, decreased pain, diminished inflammatory response, preserved postoperative pulmonary function, and more rapid return to preoperative activity [23].

We hypothesized that pulmonary lobectomy might be an indication for thoracic NOTES in the future. Therefore, a research protocol was designed to assess the feasibility of peroral transesophageal pulmonary lobectomy using the assistance of a single transthoracic trocar.

## Material and methods

### Study design

A total of 14 female pigs (*Sus scrofa domestica*) weighing 35–45 kg underwent a complex thoracic procedure by hybrid NOTES –transesophageal right upper pulmonary lobectomy using the assistance of a single transthoracic trocar. After an initial learning curve, where four animals were used to test all steps in the procedure, using different approaches, different scopes, different instruments, and different techniques (results are not reported here), 14 consecutive in vivo experiments were carried out – 10 animals in the acute study and 4 animals in a survival assessment. All surgical endoscopic and thoracoscopic procedures were recorded. Vital and physiological parameters of well-being were monitored during the experiment. The time of the procedure was recorded, as well as the difficulties and complications encountered at each step of the procedure. The animals in the survival group were monitored for 15 days. Endoscopic examination and necropsy were undertaken in all animals at the end of the protocol (after the procedure in the acute animals and after 15 days in the survival animals). The study was approved by the ethical review boards of Minho University (Braga, Portugal).



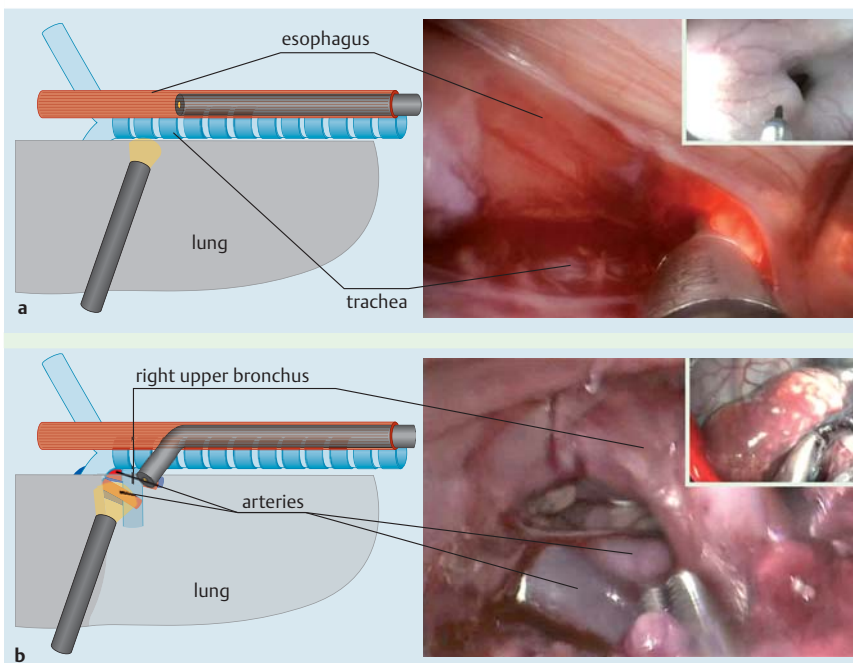
**Fig. 1** Room ergonomics. **a** Thoracoscope monitor. **b** Gastroscopist monitor. **c** Ventilator. **d** Back table for equipment.

### Pig preparation

All procedures were performed under general anesthesia with endotracheal intubation and mechanical ventilation (Fig. 1). Pigs were fasted for 8 hours and water was withheld for 4 hours before surgery. Pigs were premedicated with a combination of azaperone (4 mg/kg, intramuscularly [IM]), midazolam (1 mg/kg, IM), and atropine (0.05 mg/kg, IM). Anesthesia was induced with propofol (6 mg/kg, intravenously [IV]), and maintained with continuous propofol infusion (20 mg/kg/hour, IV) and buprenorphine (0.05 mg/kg, IM).

### Surgical technique

The main steps of the procedure described herein are schematically illustrated and can be followed in Fig. 2. The pig was placed in the prone position (Cuschieri position). A 12-mm trocar (Excel port; Ethicon Endo-Surgery, Cincinnati, Ohio, USA) was inserted on the eighth intercostal space in the right posterior axil-



**Fig. 2** Steps for transesophageal pulmonary lobectomy. Main image represents thoracoscopic view. Small upper right image represents gastroscopist view. **a** After introducing the gastroscopist into the esophagus, a 1-cm transverse esophagotomy was carried out in the upper third using an endoscopic submucosal dissection knife under thoracoscope image control. **b** Anatomic dissection of the right upper hilum was performed using flexible (gastroscopist) and rigid (thoracoscope) instruments.

Continuation see following page

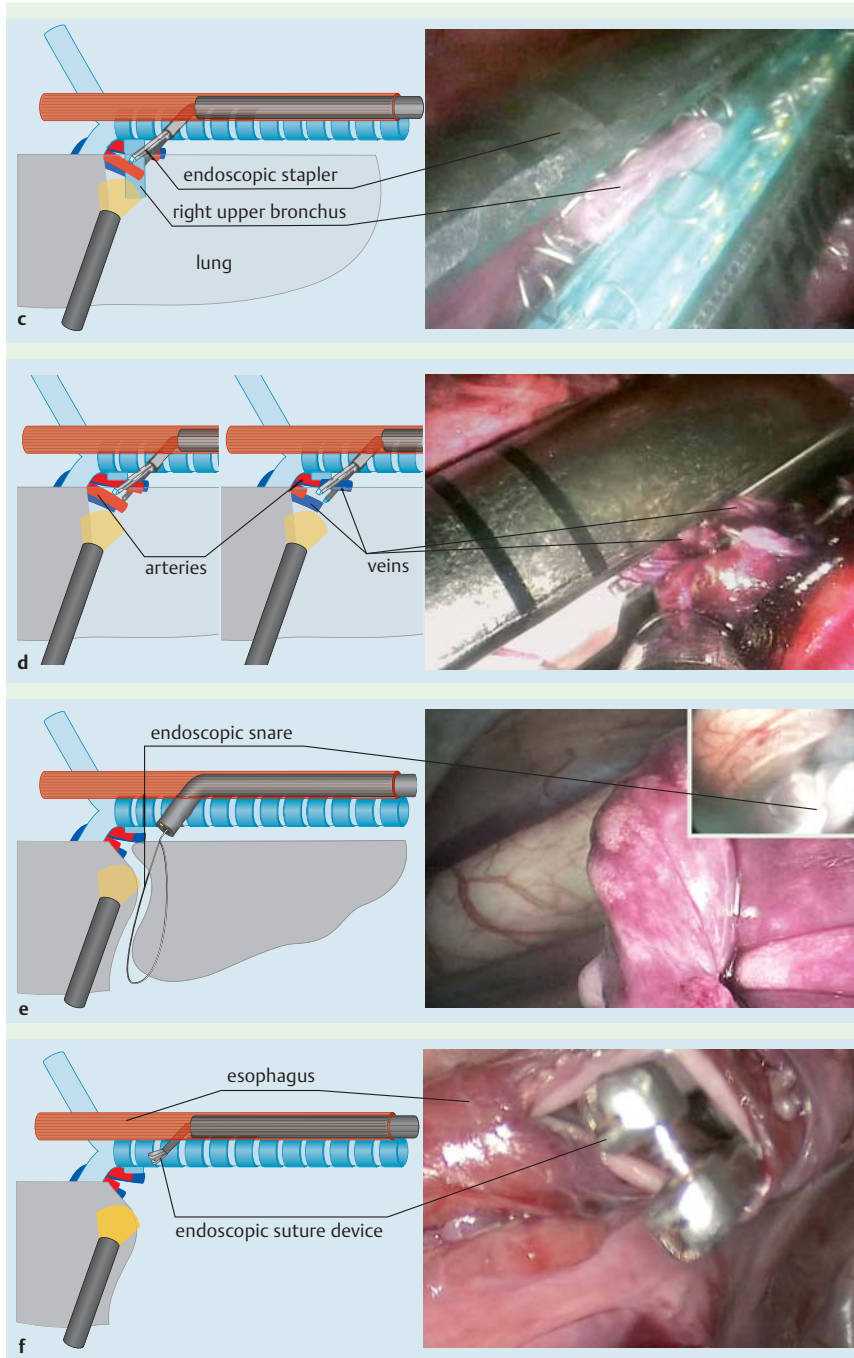


Fig. 2 continued

lary line. CO<sub>2</sub> was insufflated through this transthoracic trocar. Pressure was maintained up to 6 mmHg. An operative thoracoscope with a 5-mm working channel (Straight Forward Telescope 0° 26034AA; Karl Storz GmbH, Tuttlingen, Germany) was introduced through the trocar.

A forward-viewing double-channel gastroscope (G28/34, Karl Storz) was inserted throughout an oropharyngeal overtube (US Endoscopy, Mentor, Ohio, USA) into the esophagus (Fig. 2a). A 1-cm transverse esophagotomy was carried out in the upper third of the esophagus using a needle-knife (KD-11Q-1; Olympus, Tokyo, Japan) introduced through the gastroscope working channel. All transesophageal procedures were carried out under gastroscopic and thoracoscopic image control.

Anatomic dissection of the right upper hilum was performed using both flexible instruments (grasper 11252MX, electrocoagulation grasper 13773H; Karl Storz) and rigid devices (43-cm long,

5-mm Kelly dissector 33410ML, and scissors 34410MW; Karl Storz), which were introduced through the working channels of the gastroscope or the thoracoscope, respectively (Fig. 2b). The dissection of the pulmonary hilum was carried out from posterior to anterior. Thus, after individual dissection and isolation of the right upper bronchus and associated pulmonary arteries and veins, a long linear endostapler with distal 45° degrees of articulation freedom (EndoPath; Ethicon Endo-Surgery) was inserted through the oro-esophageal overtube. Using 45-mm load staplers, the hilum elements of the right upper lobe were divided and individually ligated with thick tissue (green) load staplers for the bronchus (Fig. 2c) and with vascular (white) load staplers for arteries and veins (Fig. 2d). After the division of the airway and vascular elements of the right upper lobe hilum, resection was completed by separating and grasping the remaining lung parenchyma through the pulmonary fissure (which is incomplete



in pig model) using a flexible endoscopic snare (110220–01; Karl Storz) with cautery (► Fig. 2e). Once released, the resected lobe was caught by the same gastroscopic snare, and the specimen was extracted retrogradely through the esophagus and mouth under image monitoring from the operative thoracoscope. After resection, the pulmonary surface was tested for air leakage under saline and high volume ventilation.

In the survival group, in addition to the surgical procedure described above, the esophagotomy was closed using one full-thickness 3–0 polyglactin stitch performed with a reticulated laparoscopy suture device (SILS stitch; Covidien, Mansfield, Massachusetts, USA) and a 5-mm knot-pusher, both introduced perorally through an overtube (US Endoscopy) and manipulated under thoracoscope image control (► Fig. 2f). Afterwards, a covered 80-mm long esophageal stent with 20-mm diameter (Hanarostent NES-00–080–070 fully covered; MITech, Seoul, Korea) was placed using a guide wire inserted through the gastroscopy. Both endoscopic and thoracoscopic visual assistance were used to position the upper limit of the esophageal stent 5 cm above the esophagotomy. Saline was injected through the gastroscopy and signs of leakage were checked using thoracoscopic visualization. At the end of the procedure, the pneumothorax was drained using a thoracic tube introduced through the transthoracic trocar. No tube was left in place. The trocar skin incision was sutured using non-absorbable independent stitches.

### Postoperative care (survival group)

At the end of the surgical intervention, all animals received a single dose of buprenorphine (0.05 mg/kg, IM) and meloxicam (0.4 mg/kg, IM). Antibiotic ceftiofur hydrochloride (5 mg/kg, IM) was repeated at 24-hour intervals for three consecutive days. A regular diet was resumed 8 hours after surgery. The animals were closely monitored for any signs of postoperative complications, distress, behavioral changes, anorexia, or weight loss. After the follow-up period, the animals were anesthetized for endoscopic examination and esophageal stent removal. Necropsy was then performed to check the healing of the esophagus wall incision and for signs of pulmonary complications.

## Results

The overall results of the study are summarized in ► Table 1. The prone approach and CO<sub>2</sub> insufflation facilitated good exposure of the intrathoracic esophagus without the need for additional retraction instruments or any kind of selective ventilation. Esophagotomy was performed safely in all animals without incident (► Fig. 2a; ► Video 1). The mean duration of esophagotomy was 5.4 ± 1.7 min.

Dissection of the right upper lobe hilum elements (bronchus, arteries, and veins) was carried out in all animals without significant problems (► Fig. 2b; ► Video 2). Pigs have an upper right bronchus emerging directly from the trachea, and the vessels (two arteries and two veins) in relation to this bronchus derive from the main pulmonary trunk vessels. Most of the dissection was done using a rigid dissector inserted through the working channel of the thoracoscope. Flexible gastroscopy instruments were essential for counter-traction and for enhancing exposure of major vessels. By introducing instruments through both the mouth and the thoracoscope, triangulation was very similar to that experienced using an exclusive thoracoscopic approach. When small vessels were disrupted, the flexible gastroscopy al-

lowed prompt suction, clear identification of hemorrhagic origin, and hemostasis using a flexible coagulation grasper introduced through its working channel. Moreover, the flexible gastroscopy was particularly useful in showing some parts of the thoracic cavity that could not be visualized with the 0° optic of the operative thoracoscope, namely lateral thoracic wall, diaphragm, and the anterior aspect of the hilum. The combination of the two endoscopic images resulted in a safer procedure.

Oro-esophageal handling of the endoscopic staplers for individual ligation of the hilum elements under transthoracic imaging was surprisingly feasible, reasonably easy to perform, and reliable in 11 cases. By stapling the bronchus first, it was possible to collapse the lobe before all of the vessels had been dissected. Therefore, after cutting the bronchus the lobe fell anteriorly, further exposing these vessels. In two cases, the ligation of the upper vessels (vein and artery) was en bloc. In one case, severe hemorrhage occurred due to incomplete vein ligation. However, even in this case, it was possible to control bleeding by grasping the hemorrhagic point with the gastroscopic grasper and using electrocoagulation alone through the dissector, which was introduced transthoracically. The mean time for hilum dissection and ligation of its elements was 44.2 ± 14.8 min (► Fig. 2c, d, ► Video 3 and ► Video 4).

After functionally excluding the right upper lobe it was easy to find the plane for lobe section once it lost ventilation and its color was changed. By inserting a grasper through the transthoracic scope, the lobe was pulled into the gastroscopy flexible snare. Lobe transection was performed using cautery in all experi-

### Video 1

Esophagotomy. Main image represents gastroscopic view, and small right upper image represents thoracoscopic view. The gastroscopy is inserted into the esophagus. With thoracoscopic assistance one can determine the exact site for esophagotomy. A 1-cm transverse esophagotomy is performed using an endoscopic submucosal dissection knife under thoracoscopy image control.

online content including video sequences viewable at:

[www.thieme-connect.de/ejournals/abstract/endoscopy/doi/10.1055/s-0031-1291594](http://www.thieme-connect.de/ejournals/abstract/endoscopy/doi/10.1055/s-0031-1291594)

### Video 2

Hilum dissection. Main image represents gastroscopic view, and small upper right image represents thoracoscopic view for 20 s (beyond 20 s only the thoracoscopic view is shown). Anatomic dissection of the right upper hilum was performed using flexible (gastroscopy) and rigid (thoracoscopy) instruments.

online content including video sequences viewable at:

[www.thieme-connect.de/ejournals/abstract/endoscopy/doi/10.1055/s-0031-1291594](http://www.thieme-connect.de/ejournals/abstract/endoscopy/doi/10.1055/s-0031-1291594)

### Video 3

Bronchus ligation. Main image represents thoracoscopic view. The right upper bronchus is stapled using a 45-mm long, linear endostapler inserted through the oro-esophageal overtube.

online content including video sequences viewable at:

[www.thieme-connect.de/ejournals/abstract/endoscopy/doi/10.1055/s-0031-1291594](http://www.thieme-connect.de/ejournals/abstract/endoscopy/doi/10.1055/s-0031-1291594)

**Table 1** Results of 10 acute and 4 survival experiments.

Case	Procedure duration, minutes			
	Esophagotomy	Dissection and ligation of hilum elements (complications)	Lobe transection and specimen retrieval (complications)	Esophagotomy closure (complications)
<b>Acute study</b>				N/A
1 <sup>1</sup>	6	60	5	N/A
2	3	60	8	N/A
3	6	54 (Small parenchymal hemorrhage controlled without the need for coagulation)	13	N/A
4	6	57	9	N/A
5	5	76	12	N/A
6	6	44	10	N/A
7	8	36 (En bloc ligation of the upper vein and artery)	14	N/A
8	7	32	5	N/A
9	4	34 (Severe hemorrhage from incomplete vein ligation, controlled with coagulation alone)	12	N/A
10	6	30 (En bloc ligation of the upper vein and artery)	7	N/A
<b>Survival study<sup>2</sup></b>				
11	3	38	5	20
12	3	38	12	24
13	5	36	9	18
14	8	24	12 (Small bronchial artery hemorrhage controlled with electrocoagulation alone; small parenchymal hemorrhage of the remaining lobe controlled with electrocoagulation alone)	18

<sup>1</sup> Died from cardiac arrest at 71 min.

<sup>2</sup> Survived for 15 days.

ments. In two cases, non-oxygenated tissue was left in place. Consequently, a second resection had to be performed. The same snare was used to retrieve the specimens through the esophagus, into the mouth. Pulmonary tissue collapsed easily permitting it to squeeze through the esophagotomy (► Fig. 2e, ► Video 5). The mean time for lobe transection and specimen retrieval was  $9.5 \pm 3.1$  min.

One animal in the acute group died before pulmonary lobectomy was completed, due to cardiac failure. All other animals were kept alive until the end of the acute experiment, at which point they were sacrificed.

In the survival group, esophagotomy closure was achieved with one or two stitches that could reasonably approximate the margins of the esophagotomy. In order to use the SILS stitch (Covidien) one has to take the gastroscope out. All of the movements of this suture device were guided by the image on the thoracoscope. The simultaneous insertion of the grasper through the working channel of the thoracoscope aided the positioning of the esophagus wall margin within the jaws of the suture device. In this way, it was possible to achieve a full-thickness wall suture of the esophagus in all experiments. Moreover, the grasper permitted the stitch to be pulled to the inside of the thorax so that the suture device could move freely without tension (► Fig. 2f, ► Video 6). After the esophageal stent was left in place, no leak-

#### Video 4

Ligation of arteries and veins. Main image represents thoracoscopic view. The arteries and the veins going to right upper bronchus are stapled using a 45-mm long, linear endostapler (introduced) through the oro-esophageal overtube.

**online content including video sequences viewable at:**

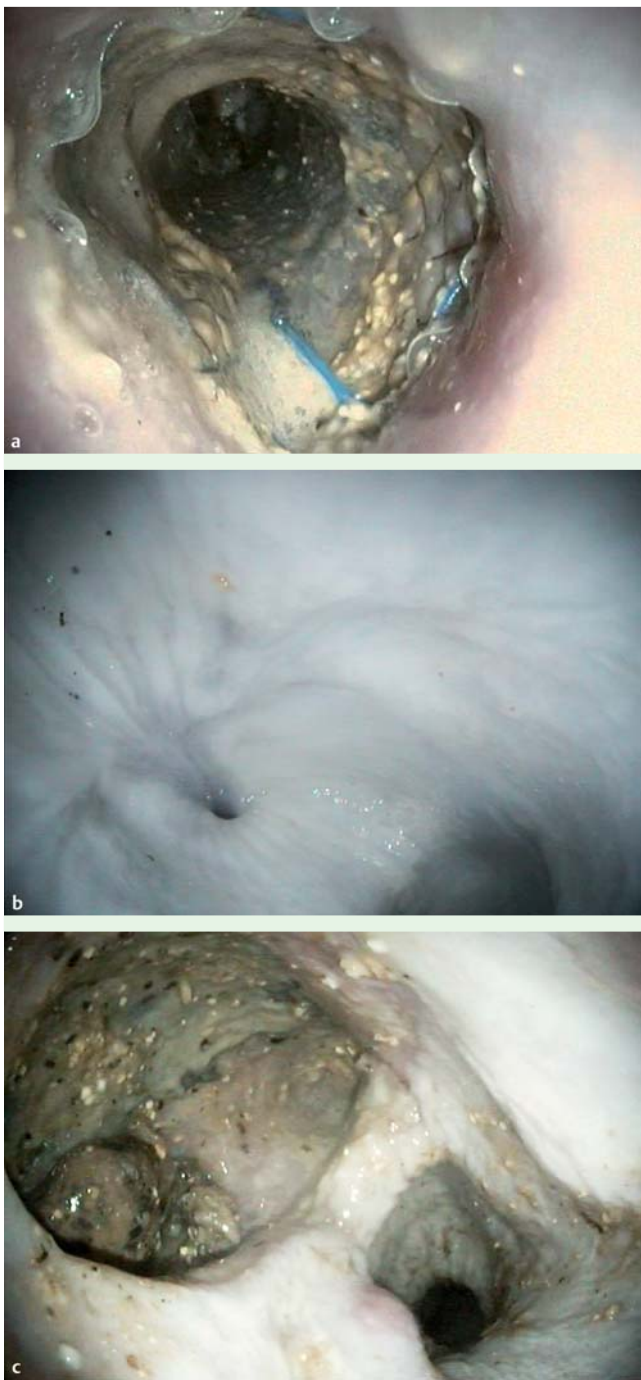[www.thieme-connect.de/ejournals/abstract/endoscopy/doi/10.1055/s-0031-1291594](http://www.thieme-connect.de/ejournals/abstract/endoscopy/doi/10.1055/s-0031-1291594)

#### Video 5

Lobe transection and specimen retrieval. Main image represents gastroscopic view, and small right upper image represents thoracoscopic view. The right upper pulmonary lobe is resected using an endoscopic snare with cautery. The specimen is extracted retrogradely through the mouth.

**online content including video sequences viewable at:**

[www.thieme-connect.de/ejournals/abstract/endoscopy/doi/10.1055/s-0031-1291594](http://www.thieme-connect.de/ejournals/abstract/endoscopy/doi/10.1055/s-0031-1291594)



**Fig. 3** Esophagotomy closure. **a** Esophageal stent in place on postoperative day 15. **b** Pseudo-diverticulum after esophageal stent removal on postoperative day 15. **c** Necrotic recess after esophageal stent removal on postoperative day 15.

#### Video 6

Esophagotomy closure. Initially only thoracoscopic view is shown. Beyond 1 min and 12s, the main image represents the gastroscopic view and small right upper image represents thoracoscopic view. The esophagotomy is stitched and tied using SILS Stitch and a long knot-pusher, which are handled through the oro-esophageal overtube. Then, the esophageal stent is left in place.

online content including video sequences viewable at:  
[www.thieme-connect.de/ejournals/abstract/endoscopy/doi/10.1055/s-0031-1291594](http://www.thieme-connect.de/ejournals/abstract/endoscopy/doi/10.1055/s-0031-1291594)

age was found. The mean time for esophagotomy closure and stent placement was  $20.0 \pm 2.8$  min. The total mean operative time in the survival group was  $68.7 \pm 6.4$  min.

All four animals in the survival group survived for 15 days. After recovery of anesthesia, the pigs tolerated a regular diet starting 8 hours after surgery, and they ambulated freely and displayed normal behavior. No adverse event occurred during the survival period. Endoscopic examination before necropsy revealed a pseudo-diverticulum in one animal (● Fig. 3 a, b), and wound dehiscence with confined collection/recess in the remaining three animals. These findings suggest incomplete healing of the esophagotomy. The esophageal necrotic recess did not communicate with the thorax or the pericardium (● Fig. 3 c). No stent migration was observed. No esophageal strictures were found. Post-mortem examination revealed pleural adhesions on the site of pulmonary lobectomy. There were no signs of infection in the ipsilateral or counter-lateral lung parenchyma.

#### Discussion

VATS is becoming the gold standard for pulmonary lobectomy for both benign and oncologic diseases [18–23]. In NOTES, video-assisted thoracoscopy may be performed by a transesophageal approach, thereby avoiding intercostal neuralgia and reducing post-operative pain for the patient [6]. In porcine models, the transesophageal approach permitted mediastinoscopy and thoracoscopy, lung and pleura biopsy, lymphadenectomy, pericardial fenestration, vagotomy and esophagomyotomy, Heller myotomy, esophageal wall resection, and sympathectomy [1,5–11]. More recently, Rolanda et al. established the concept of hybrid thoracic NOTES. By introducing a transthoracic trocar, the authors overcame some potential risks of the transesophageal approach, namely blind esophagotomy creation, esophagotomy closure, and thoracic drainage at the end of the procedure. Furthermore, triangulating instruments inserted through the flexible gastroscope and the transthoracic working channel, and the images provided by both scopes permitted a complex intra-thoracic procedure to be performed – segmental esophagectomy with esophago-esophageal anastomosis [12].

As discussed earlier, the prone position allows gravity to provide good esophageal exposure with minimal handling. It was not necessary to retract the lung and therefore the transthoracic instruments could be focused on the complex surgical procedure. The thoracic trocar was very useful for CO<sub>2</sub> insufflation and also for pressure control. It also permitted control of the esophagotomy, which was performed from inside to outside of the esophagus; by locating the exact position (side and level) for esophagotomy creation, the thoracic trocar assisted the gastroscope in achieving the best approach to the pulmonary hilum. Furthermore, when the procedure was completed, the trocar site was used for tube insertion and acute pleural drainage. This port might be important in the human setting, as such a procedure would not be attempted without at least 24 hours of thoracic drainage.

Combining two opposite sites, for the entrance of scopes and respective instruments, regular triangulation and counter-traction could be achieved, which simulate the two hand movements of the surgeon, promoting secure manipulation of tissues, careful dissection of the pulmonary hilum, and effective electrocoagulation for hemorrhagic control. As mentioned earlier, the flexible endoscope inside the thorax makes it possible to examine the



whole cavity including sites where rigid transthoracic endoscopes cannot reach – namely the chest wall. It should be emphasized that flexible instruments were used and the gastroscope was introduced through the mouth but rigid instruments such as the staplers, the SILS stitch, and the knot-pusher were also used. In fact, the use of an oro-esophageal overtube permitted the rapid access of all of these instruments into the thoracic cavity. Coordinating the movement of a rigid instrument through the mouth with the image provided by the thoracoscope is what made the ligation of the right upper bronchus and its vessels possible and reliable. Moreover, the rigid dissector inserted through the operative thoracoscope made positioning easier and faster. As the same endoscopic stapler was used throughout the first nine experiments, it is possible that failure to completely ligate the pulmonary veins was due to ineffective stapling related to detrition of equipment. A new stapler was used after this event, and no further failures occurred.

Various solutions for endoscopic esophagotomy closure have been suggested. Creation of a submucosal tunnel that will not require mucosal suture has been used the most [1, 7], but it would not permit the retrieval of large specimens. The self-approximating transluminal access technique that has been used successfully in transgastric procedures even with specimen retrieval [24] would not work in this case, because during pulmonary lobe retrieval esophageal mucosa is easily disrupted. Endoscopic clips, suturing systems prototypes [6], esophageal stents [25], T-tags [26], and Padlock G clips [27] have also been suggested, but none of them seems to be completely reliable, especially after specimen retrieval, nor are they readily available. In the current study, a novel technique has been described for full wall thickness esophagotomy closure, using a conventional laparoscopic suture device. Although the esophagotomy closure was not complete with the SILS stitch application, combining it with an esophageal stent provided closure with a good survival rate. Endoscopic signs of incomplete esophageal closure associated with collection were found in three survival experiments, after esophageal stent removal 15 days after the procedure. This might have been too soon for removal of stents; most authors would recommend leaving the esophageal stent in place for at least 6 weeks [28]. Another cause for wound dehiscence with necrotic recess could be related to the fact that the suture was applied longitudinally, rather than in a transverse manner. This resulted in the partial esophageal stricture that was observed during esophageal stent placement. Esophageal stents, with their circumferential strength, are a recognized treatment alternative for esophageal strictures [29]. In fact, none of the pigs in the survival group showed signs of stricture 15 days after surgery, although stricture may have been avoided by stitch rupture in the early postoperative days. Finally, feeding the animals 8 hours after surgery might have been too soon, as this could favor local contamination. Even though the infection associated with wound dehiscence was confined and separated from both the pericardium and lungs, the high incidence of esophageal wound dehiscence makes us reluctant to suggest this closure method at this stage. Further development of endoscopic devices will provide safer solutions in the future.

Survival experiments were essential to prove that transesophageal pulmonary lobectomy was not only feasible but also reliable. Even without any thoracic tube drainage, other than the one performed immediately after esophageal closure, and without any postoperative respiratory support, all the animals survived, with no thoracic sequelae besides local pleural adhesions. Infection

was prevented by a 3-day antibiotic regimen, and no pulmonary or pericardial complications were noted, other than local pleural adhesions. Again, by using a hybrid NOTES approach, it was possible to perform major thoracic surgery both safely and reliably in the porcine model. The animal model is certainly a limitation of the current study; in fact the porcine anatomy is somewhat different from the human anatomy. The independent right upper bronchus emerging directly from the trachea facilitates its dissection and ligation using the endoscopic stapler coming from the esophagus. Furthermore, human cadaver studies are not possible for procedures in the lung. This is the main reason why all published transesophageal NOTES procedures have been performed in the porcine model [1 – 12].

Results from the acute study demonstrated that transesophageal NOTES, with the assistance of a single transthoracic trocar, can be used for highly complex thoracic procedures. Moreover, the survival protocol confirmed the reliability of the procedure, and it must be stressed, without any special care frequently used for thoracic interventions – minimal aseptic precautions, no thoracic drain left in place, no intensive care support, and almost immediate food ingestion ad libitum.

In conclusion, transesophageal right upper pulmonary lobectomy using single transthoracic trocar assistance is feasible and may represent a step towards scar-free pulmonary lobectomy.

**Competing interests:** J. Correia-Pinto is a consultant for Karl Storz GmbH.

#### Institutions

- <sup>1</sup> Life and Health Sciences Research Institute (ICVS), School of Health Sciences, University of Minho, Braga, Portugal
- <sup>2</sup> ICVS/3B's – PT Government Associate Laboratory, Braga/Guimarães, Portugal
- <sup>3</sup> Department of Pediatric Surgery, Centro Hospitalar do Porto, Porto, Portugal
- <sup>4</sup> Department of Gastroenterology, Hospital de Braga, Braga, Portugal
- <sup>5</sup> Department of Pediatric Surgery, Hospital de Braga, Braga, Portugal

#### Acknowledgment

This project was funded by the FCT Grants project PTDC/SAU-OSM/105578/2008.

#### References

- 1 Sumiyama K, Goustout CJ, Rajan E et al. Transesophageal mediastinoscopy by submucosal endoscopy with mucosal flap safety valve technique. *Gastrointest Endosc* 2007; 65: 679 – 683
- 2 Lima E, Henriques-Coelho T, Rolanda C et al. Transvesical thoracoscopy: a natural orifice transluminal endoscopic approach for thoracic surgery. *Surg Endosc* 2007; 21: 854 – 858
- 3 De Palma GD, Siciliano S, Addeo P et al. A NOTES approach for thoracic surgery: transgastric thoracoscopy via a diaphragmatic incision in a survival porcine model. *Minerva Chir* 2010; 65: 11 – 15
- 4 Yang C, Liu HP, Chu Y et al. Natural orifice transtracheal evaluation of the thoracic cavity and mediastinum. *Surg Endosc* 2010; 24: 2905 – 2907
- 5 Willingham FF, Gee DW, Lauwers GY et al. Natural orifice transesophageal mediastinoscopy and thoracoscopy. *Surg Endosc* 2008; 22: 1042 – 1047
- 6 Fritscher-Ravens A, Patel K, Ghanbari A et al. Natural orifice transluminal endoscopic surgery (NOTES) in the mediastinum: long-term survival animal experiments in transesophageal access, including minor surgical procedures. *Endoscopy* 2007; 39: 870 – 875
- 7 Gee DW, Willingham FF, Lauwers GY et al. Natural orifice transesophageal mediastinoscopy and thoracoscopy: a survival series in swine. *Surg Endosc* 2008; 22: 2117 – 2122
- 8 Woodward T, McCluskey D, Wallace MB et al. Pilot study of transesophageal endoscopic surgery: NOTES esophagomyotomy, vagotomy, lymphadenectomy. *J Laparoendosc Adv Surg Tech* 2008; 18: 743 – 745



- 9 Pauli EM, Mathew A, Halick RS et al. Technique for transesophageal endoscopic cardiomyotomy (Heller myotomy): video presentation at the Society of American Gastrointestinal and Endoscopic Surgeons (SAGES). *Surg Endosc* 2008; 22: 2279–2280
- 10 Frischer-Ravens A, Cuming T, Jacobsen B et al. Feasibility and safety of endoscopic full-thickness esophageal wall resection and defect closure: a prospective long-term survival animal study. *Gastrointest Endosc* 2009; 69: 1314–1320
- 11 Turner BG, Gee DW, Cizginer S et al. Feasibility of endoscopic transesophageal thoracic sympathectomy. *Gastrointest Endosc* 2010; 71: 171–175
- 12 Rolanda C, Silva D, Branco C et al. Peroral esophageal segmentectomy and anastomosis with single transthoracic trocar assistance: a step forward in thoracic NOTES. *Endoscopy* 2011; 43: 14–20
- 13 Allen MS, Deschamps C, Lee RE et al. Video-assisted thoracoscopic stapled wedge excision for indeterminate pulmonary nodules. *J Thorac Cardiovasc Surg* 1993; 106: 1048–1052
- 14 Hazelrigg SR, Nunchuck SK, LoCicero J et al. Video-assisted Thoracic Surgery Study Group data. *Ann Thorac Surg* 1993; 36: 1039–1043
- 15 Lewia RJ, Caccavale RJ, Sisler GE et al. One hundred consecutive patients undergoing video-assisted thoracic operations. *Ann Thorac Surg* 1992; 54: 421–426
- 16 Coltharp WH, Arnold JH, Alford WC et al. Videothoracoscopy: improved technique and expanded indications. *Ann Thorac Surg* 1992; 53: 776–778
- 17 Tomaszek SC, Cassivi SD, Shen KR et al. Clinical outcomes of video-assisted thoracoscopic lobectomy. *Mayo Clin Proc* 2009; 84: 509–513
- 18 McKenn jr RJ, Houck W, Fuller CB. Video-assisted thoracic surgery lobectomy: experience with 1,100 cases. *Ann Thorac Surg* 2006; 81: 421–425
- 19 Nicastrì DG, Wisnivesky JP, Little VR et al. Thoracoscopic lobectomy: report on safety, discharge independence, pain, and chemotherapy tolerance. *J Thorac Cardiovasc Surg* 2008; 135: 642–647
- 20 Sakuraba M, Miyamoto H, Oh S et al. Video-assisted thoracoscopic lobectomy vs. conventional lobectomy via open thoracotomy in patients with clinical stage IA non-small cell lung carcinoma. *Interact Cardiovasc Thorac Surg* 2007; 6: 614–617
- 21 Solaini L, Prusciano F, Bagioni P et al. Long-term results of video-assisted thoracic surgery lobectomy for stage I non-small cell lung cancer: a single-centre study of 104 cases. *Interact Cardiovasc Thorac Surg* 2004; 3: 57–62
- 22 Swanson SJ, Herndon JE, 2nd, D'Amico TA et al. Video-assisted thoracic surgery lobectomy: report of CALGB 39802 – a prospective, multi-institution feasibility study. *J Clin Oncol* 2007; 25: 4993–4997
- 23 Onatis MW, Petersen RP, Balderson SS et al. Thoracoscopic lobectomy is a safe and versatile procedure: experience with 500 consecutive patients. *Ann Surg* 2006; 244: 420–425
- 24 Moyer MT, Pauli EM, Gopal J et al. Durability of the self-approximating transluminal access technique (STAT) for potential use in natural orifice transluminal surgery (NOTES). *Surg Endosc* 2011; 25: 315–321
- 25 Fischer A, Thomusch O, Benz S et al. Nonoperative treatment of 15 benign esophageal perforations with self-expandable covered metal stents. *Ann Thorac Surg* 2006; 81: 467–472
- 26 Bhat YM, Hegde S, Knaus M et al. Transluminal endosurgery: novel use of endoscopic tacks for the closure of access sites in natural orifice transluminal endoscopic surgery (with videos). *Gastrointest Endosc* 2009; 69: 1161–1166
- 27 Romanelli JR, Desilets DJ, Earle DB. Natural orifice transluminal endoscopic surgery gastrotomy closure in porcine explants with the Padlock-G clip using the Lock-It system. *Endoscopy* 2010; 42: 306–310
- 28 van Heel NC, Haringsma J, Spaander MC et al. Short-term esophageal stenting in the management of benign perforations. *Am J Gastroenterol* 2010; 105: 1515–1520
- 29 Thomas T, Abrams KR, Subramanian V et al. Esophageal stents for benign refractory strictures: a meta-analysis. *Endoscopy* 2011; 43: 386–393