

African Journal of Paediatric Surgery

| Volume 9 | Issue 2 | May-Aug 2012 |

In this issue:

- Is there a role for open surgery in the management of the undescended testis?
- Dismembered pyeloplasty for ureteropelvic junction syndrome treatment in children
- Six-year retrospective analysis of colonic perforation in neonates and infants: Single centre experience
- Laparoscopic management of 128 undescended testes: Our experience
- Does circumcision alter the periurethral uropathogenic bacterial flora
- Early oral feeding following intestinal anastomoses in children is safe
- Retrospective analysis of paediatric achalasia in India: Single centre experience
- Impact of magnetic resonance urography and ultrasonography on diagnosis and management of hydronephrosis and megaureter in paediatric patients

Official Journal of:
Association of Paediatric Surgeons of Nigeria [APSON]
Pan-African Paediatric Surgical Association [PAPSA]

Dismembered pyeloplasty for ureteropelvic junction syndrome treatment in children

João Moreira-Pinto^{1,3}, Angélica Osório¹, Fernando Vila², João Luís Ribeiro de Castro¹, Armando Réis²

Access this article online

Website:
www.afripaedsurg.org

DOI:
10.4103/0189-6725.99392

PMID:

Quick Response Code:



ABSTRACT

Background: Open dismembered pyeloplasty remains the preferred surgical technique for ureteropelvic junction syndrome (UPJS) in most paediatric urology units. The authors present their experience of 230 patients and describe their form of presentation, treatment and early and long-term results. **Materials and Methods:** Retrospective analysis of clinical records of 230 patients submitted to dismembered pyeloplasty in an 8-year period, from 1999 until 2007. Pre-operative data, early and long-term complications were registered. Image studies included renopelvic ultrasonography, mercapto-acetyl triglycine (MAG3) renal scan with furosemide test and, in some cases, elimination urography and retrograde cystography. Pre-operative and post-operative results were compared. **Results:** Median age of our patients at time of surgery was 14.9 months (range: 21 days until 16.6 years). The majority of patients were male (72%, n = 166) and 74% (n = 120) had pre-natal diagnosis. The majority of hydronephrosis were in the left side (61%, n = 141). There were only 3% of complications in early post-operative period: four had acute pyelonephritis, two had renocutaneous fistula and one died due to respiratory failure. Mean follow-up period was 5 years, ranging from 12 months to 9.7 years. There was only one case of recurrence with the need of reoperation. Comparing pre-operative and post-operative imaging results, we found that 89% had normal renal function, 7% diminished but better than before and 2% equal as before surgery. **Conclusion:** Open dismembered pyeloplasty is a safe and effective treatment in paediatric UPJS.

Key words: Adolescent, child, hydronephrosis, pyeloplasty, ureteropelvic junction obstruction

One of the most common pathologies in paediatric urology units is ureteropelvic junction syndrome (UPJS). It represents the most common cause for hydronephrosis in children.^[1] Despite recent advances in minimally invasive techniques, open dismembered pyeloplasty remains the preferred surgery for correction of ureteropelvic obstruction in most paediatric urology units. In this study, we present our experience with open pyeloplasty in the last 8 years.

MATERIAL AND METHODS

We retrospectively reviewed the clinical charts of all patients submitted to dismembered pyeloplasty from 1999 until 2007. Indications for surgery were symptomatic obstruction and asymptomatic obstruction with an impaired split renal function less than 40%, or a decrease of split renal function of more than 10% in subsequent studies. In case of bilateral UPJS, the two kidneys were not approached simultaneously. The kidney showing worst obstruction pattern was operated first.

Anderson-Hynes type dismembered pyeloplasty was performed retroperitoneally through flank incision. Double J catheter was placed in an antegrade fashion after the posterior wall of the pyeloureteric anastomoses was completed. All patients had a perinephric drain and Foley catheter placed. Foley catheter was removed on post-operative day 1 or 2, and if the perinephric drain output remained minimal, it was removed on the same day.

Ceftriaxone IV was administered for prophylaxis before surgery. Trimethoprim-sulfamethoxazole PO was continued until Double J catheter was removed 4 to 6 weeks after surgery. The Double J catheter was removed cystoscopically under general anaesthesia.

Follow-up imaging consisted of ultrasound at 1 month post-operatively. A renal scan was performed 4 to 6 months later. Further imaging examinations were

Departments of ¹Pediatric Surgery, and ²Urology, Centro Hospitalar do Porto, Porto, Portugal, ³Life and Health Sciences Research Institute, University of Minho, Braga, Portugal

Address for correspondence:

Dr. João Moreira-Pinto,
Serviço de Cirurgia Pediátrica, Centro Hospitalar do Porto, Rua da Boavista, 827, 4050-111 Porto, Portugal.
E-mail: moreirapinto@gmail.com

based on surgeon preference and degree of improved hydronephrosis.

We analysed pre-operative data, short- and long-term complications. Image studies included renal and vesical ultrasonography, MAG3 renal scan followed by furosemide administration and in some cases intravenous urography. Retrograde urography was performed in all patients with previous history of urinary infection. Pre-operative and post-operative results were compared.

RESULTS

During the period going from 1st January, 1999 until 31st December, 2007, 230 children were surgically treated for UPJS in our institution. 165 (72%) were males and 65 (28%) were females. All of them were submitted to Andersen-Hynes dismembered pyeloplasty. Ureteropelvic obstruction was left sided in 141 children (61%), right sided in 86 (37%) and bilateral in 3 (2%) [Figure 1]. A total of 233 pyeloplasties were performed.

In 74% (n = 166), there was prenatal diagnosis, against 26% (n = 64) that had no prenatal diagnosis. Fifty patients in the group without prenatal diagnosis had one or more symptoms [Table 1]. In the remaining 14, UPJS was an incidental finding.

Age average was 17 months in the prenatal diagnosis group (median = 9 months; range, 21 days – 14 years) and 8 years in the group without prenatal diagnosis (median = 8.3 years; range, 2.7 months – 15 years) [Figure 2].

Concerning immediate post-operative complications, there were four acute pyelonephritis and two

renocutaneous fistulas. One child died because of respiratory distress one hour after surgery, what interpreted as an anaesthetic complication. There was only one case of pyeloplasty redo, due to UPJS persistence.

Mean follow-up period was 5 years, ranging from 12 months to 9.7 years. Comparing image studies from pre-operative and post-operative period, we found that 89% had a normal renal function, 7% had it diminished but somehow better and 2% had no recovery in renal function [Figure 3].

DISCUSSION

UPJS represents the dilatation of renal pelvis due to obstruction in the ureteropelvic junction. UPJS is the most frequent urological malformation (40-60%), and it can be bilateral in 10% to 20% of the cases.^[1,2] The first reconstructive procedure of the ureteropelvic junction was performed by Kuster in 1891. In 1949, when Anderson and Hynes described their technique consisting of dismembered pyeloplasty with ureteral spatulation, the procedure widespread and rapidly became the most common procedure for UPJS.^[3] The morbidity associated to lumbotomy incision forced the development of new minimally invasive techniques: antegrade endopyelotomy, retrograde endopyelotomy,

Table 1: Presenting symptoms of patients without prenatal diagnosis

Number	Presenting symptoms
24	Abdominal pain
20	Urinary infection
5	Nocturnal enuresis
5	Haematuria
1	Frequent vomiting

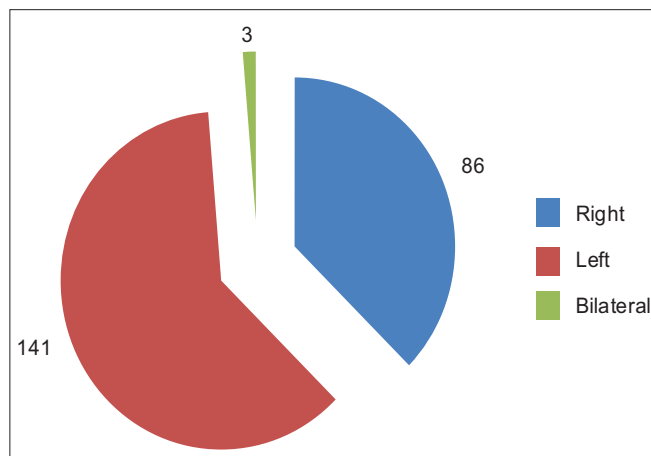


Figure 1: Distribution by ureteropelvic junction syndrome side

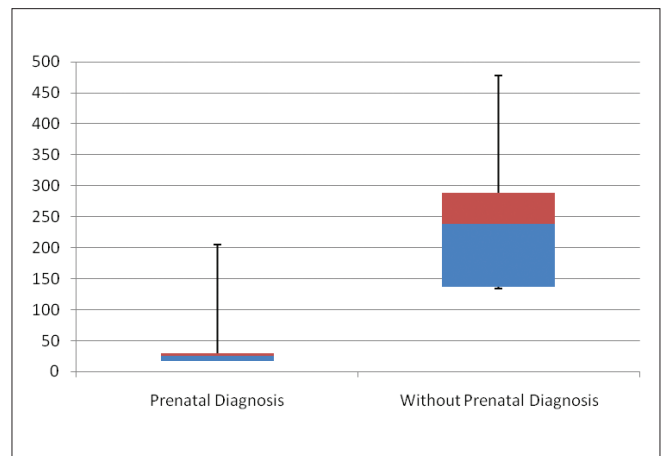


Figure 2: Distribution by age

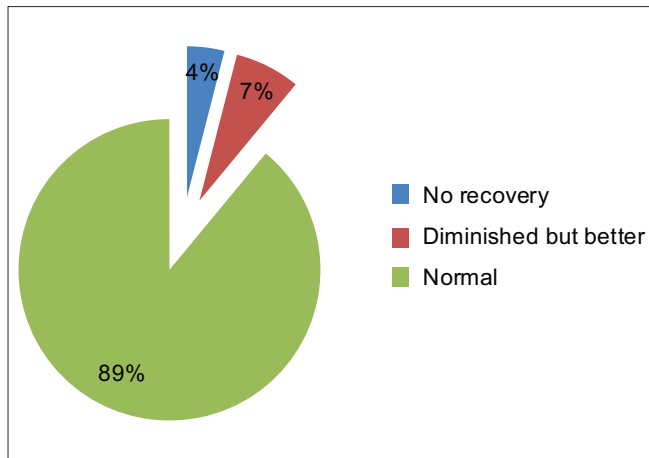


Figure 3: Comparison preoperative and post-operative of image studies results

retrograde endopyelotomy with electrosurgical cutting wire and low-pressure tamponade balloon (Acucise) and laparoscopic pyeloplasty.^[4]

Growing evidence suggests that laparoscopic pyeloplasty is becoming the standard of care in adults. However, to date, only few comparative paediatric studies of conventional laparoscopic and open pyeloplasties have been reported.^[5-9] Analysing these reports, laparoscopy is associated with shorter hospital stay, less narcotic use and less pain. On the other hand, laparoscopic pyeloplasty implies a longer operative time and seems associated with more urinary leaks. The short number of patients and the short follow-up period is insufficient to draw solid conclusions.^[9] Regarding the heterogeneity of the published result, it seems clear that surgeon experience, equipment available and the correct selection of the patient are key elements for the success of these techniques.^[10-12] Open dorsal lumbar approach for dismembered pyeloplasty in children has been previously shown to be safe and efficacious in the treatment of UPJS.^[13] Ureteral catheters help align the anastomosis, allowing to heal in a straight, dependent position and, thus avoiding the risk of ureteral kinking and late recurrent obstruction. Furthermore, the combination of ureteral stent placement and indwelling catheter drainage for 24 to 48 hours after surgery may prevent urine leakage at the anastomotic site and potentially avoid a local inflammatory reaction.^[14] Our series of 230 patients shows a low complication rate (3%), with only one UPJS persistence. These findings are consistent with those presented by other authors.^[8,13-15]

In our series, we found that 98% had either normal or some recovery in their renal function post-operatively. There is little data in the literature on functional

improvement in renal function. Wang *et al.*, presented a series of 30 patients, 91% to 92% were stable or had improved differential renal function 5 years after surgery.^[16] O'Reilly presents a series of 26 UPJS patients, of which 10 had their renal function improved post-operatively and 16 remained the same (8 normal and 8 reduced pre-operatively).^[17] We believe that the high success rate in our study might be related with early surgical treatment.

CONCLUSIONS

Open dismembered pyeloplasty is a safe and effective treatment for UPJS in the paediatric population and it remains the first choice in the treatment of ureteropelvic obstruction in our unit.

ACKNOWLEDGMENTS

The authors would like to thank all the paediatricians who helped us following up our patients: Dr. Abílio Guimarães (Ovar), Dra. Célia Madalena (Póvoa de Varzim), Dra. Conceição Mota (Porto), Dra. Cristina Miguel (Famalicão), Dra. Edite Tomás (Penafiel), Dr. Elói Pereira (Porto), Dra. Fátima Dias (Vila Real), Dra. Graça Ferreira (Vila Nova de Gaia), Dra. Helena Silva (Braga), Dr. Humberto Fernandes (Barcelos), Dra. Idalina Maciel (Viana do Castelo), Dr. Jorge Vaz Duarte (Aveiro), Dr. José Carlos Matos (Chaves), Dra. Judite Marques (Bragança), Dra. Laura Soares (Oliveira de Azeméis), Dra. Liliana Rocha (Porto) Dra. Manuela Ferreira (Bragança), Dr. Matos Marques (Braga), Dr. Óscar Vaz (Mirandela), Dra. Paula Matos (Porto), Dra. Paula Rocha (Aveiro), Dr. Paulo Teixeira (Famalicão), Dra. Ricardo Araújo (Santa Maria da Feira), Dra. Sameiro Faria (Porto), Dra. Teresa Costa (Porto), Dr. Virgílio Oliveira (Amarante).

REFERENCES

1. Thomas DF. Prenatally diagnosed urinary tract abnormalities: Long-term outcome. *Semin Fetal Neonatal Med* 2008;13:189-95.
2. Ferhi K, Rouprêt M, Misraï V, Renard-Penna R, Chartier-Kastler E, Richard F, *et al.* Functional outcomes after pure laparoscopic or robot-assisted pyeloplasty. *Actas Urol Esp* 2009;33:1103-7.
3. Gamarra Quintanilla M, Ibarluzea González C, Gallego Sánchez JA, Camargo Ibarra I, Pereira Arias JG, Astobieta Odriozola A, *et al.* [New position for laparoscopic pyeloplasty. Our experience]. [Article in Spanish]. *Arch Esp Urol* 2007;60:565-8.
4. Bestard Vallejo JE, Cecchini Rosell L, Raventós Busquets CX, Trilla Herrera E, Tremps Velázquez E, Morote Robles J. Open versus laparoscopic pyeloplasty: Review of our series and description of our laparoscopic pyeloplasty procedure [Article in Spanish]. *Actas Urol Esp* 2009;33:994-9.
5. Bonnard A, Fouquet V, Carricaburu E, Aigrain Y, El-Ghoneimi A. Retroperitoneal laparoscopic versus open pyeloplasty in children. *J Urol* 2005;173:1710-3.
6. Ravish IR, Nerli RB, Reddy MN, Amarkhed SS. Laparoscopic pyeloplasty compared with open pyeloplasty in children. *J Endourol*

- 2007;21:897-902.
7. Piaggio LA, Franc-Guimond J, Noh PH, Wehry M, Figueroa TE, Barthold J, *et al.* Transperitoneal laparoscopic pyeloplasty for primary repair of ureteropelvic junction obstruction in infants and children: Comparison with open surgery. *J Urol* 2007;178:1579-83.
 8. Penn HA, Gatti JM, Hoestje SM, DeMarco RT, Snyder CL, Murphy JP. Laparoscopic versus open pyeloplasty in children: Preliminary report of a perspective randomized trial. *J Urol* 2010;184:690-5.
 9. Braga LH, Lorenzo AJ, Bägli DJ, Mahdi M, Salle JL, Khoury AE, *et al.* Comparison of flank, dorsal lumbotomy and laparoscopic approaches for dismembered pyeloplasty in children older than 3 years with ureteropelvic junction obstruction. *J Urol* 2010;183:306-11.
 10. Romero Otero J, Gómez Fraile A, Blanco Carballo O, Aransay Bramtot A, López Vázquez F, Lovaco Castellano F. Endourological treatment of pelviureteric junction obstruction in paediatric patients: Our experience [Article in Spanish]. *Actas Urol Esp* 2007;31:146-52.
 11. Lopez M, Guye E, Varlet F. Laparoscopic pyeloplasty for repair of pelvi-ureteric junction obstruction in children. *J Pediatr Urol* 2009;5:25-9.
 12. Nerli RB, Reddy M, Prabha V, Koura A, Patne P, Ganesh MK. Complications of laparoscopic pyeloplasty in children. *Pediatr Surg Int* 2009;25:343-7.
 13. Wiener JS, Roth DR. Outcome based comparison of surgical approaches for pediatric pyeloplasty: Dorsal lumbar versus flank incision. *J Urol* 1998;159:2116-9.
 14. Braga LH, Lorenzo AJ, Bägli DJ, Keays M, Farhat WA, Khoury AE, *et al.* Risk factors for recurrent ureteropelvic junction obstruction after open pyeloplasty in a large pediatric cohort. *J Urol* 2008;180:1684-7.
 15. Williams B, Tareen B, Resnick MI. Pathophysiology and treatment of ureteropelvic junction obstruction. *Curr Urol Rep* 2007;8:111-7.
 16. Wang TM, Chang PL, Kao PF, Hsieh ML, Huang ST, Tsui KH. The role of diuretic renography in the evaluation of obstructed hydronephrosis after pediatric pyeloplasty. *Chang Gung Med J* 2004;27:344-50.
 17. O'Reilly PH. Functional outcome of pyeloplasty for ureteropelvic junction obstruction: Prospective study in 30 consecutive cases. *J Urol* 1989;142:273-6.

Cite this article as: Moreira-Pinto J, Osório A, Vila F, de Castro JR, Réis A. Dismembered pyeloplasty for ureteropelvic junction syndrome treatment in children. *Afr J Paediatr Surg* 2012;9:98-101.

Source of Support: Nil. **Conflict of Interest:** None declared.

Announcement

Android App



Download
**Android
application**

FREE

A free application to browse and search the journal's content is now available for Android based mobiles and devices. The application provides "Table of Contents" of the latest issues, which are stored on the device for future offline browsing. Internet connection is required to access the back issues and search facility. The application is compatible with all the versions of Android. The application can be downloaded from <https://market.android.com/details?id=comm.app.medknow>. For suggestions and comments do write back to us.