

## Clinicopathological Correlation and Prognostic Significance of VEGF-A, VEGF-C, VEGFR-2 and VEGFR-3 Expression in Colorectal Cancer

SANDRA F. MARTINS<sup>1,2,3</sup>, EDUARDO A. GARCIA<sup>4,5</sup>, MARCUS ALEXANDRE MENDES LUZ<sup>4</sup>, FERNANDO PARDAL<sup>6</sup>, MESQUITA RODRIGUES<sup>7</sup> and ADHEMAR LONGATTO FILHO<sup>1,2,5,8</sup>

<sup>1</sup>Life and Health Sciences Research Institute (ICVS), School of Health Sciences, University of Minho, Braga, Portugal;

<sup>2</sup>ICVS/3B's, PT Government Associate Laboratory, Braga/Guimarães, Portugal;

<sup>3</sup>Surgery Department, Hospital Center of Trás-os-Montes e Alto Douro, Vila Real, Portugal;

<sup>4</sup>Paulo Prata Faculty of Health Sciences, Barretos, São Paulo, Brazil;

<sup>5</sup>Molecular Oncology Research Center, Barretos Cancer Hospital, Barretos, São Paulo, Brazil;

<sup>6</sup>Pathology Department, Braga Hospital, Braga, Portugal;

<sup>7</sup>Coloproctology Unit, Braga Hospital, Braga, Portugal;

<sup>8</sup>Laboratory of Medical Investigation (LIM) 14, Faculty of Medicine, University of São Paulo, São Paulo, Brazil

**Abstract.** *Background:* Colorectal cancer (CRC) is the third most common type of cancer and the fourth most frequent cause of cancer death. Literature indicates that vascular endothelial growth factor is a predominant angiogenic factor and that angiogenesis plays an important role in the progression of CRC. *Patients and Methods:* The present series consisted of tissue samples obtained from 672 patients who had undergone large bowel resection between 2005 and 2010 at the Braga Hospital, Portugal. Archival paraffin-embedded CRC tissue and normal adjacent samples were used to build up tissue microarray blocks and VEGF-A, VEGF-C, VEGFR-2 and VEGFR-3 expression was immunohistochemically assessed. *Results:* We observed an overexpression of VEGF-C in CRC when tumour cells and normal-adjacent tissue were compared ( $p=0.004$ ). In tumour samples, VEGF-C-positive cases were associated with VEGFR-3 expression ( $p=0.047$ ). When assessing the

correlation between VEGF-A, VEGF-C, VEGFR-2 and VEGFR-3 expressions and the clinicopathological data, it was revealed that VEGF-A positive cases were associated with male gender ( $p=0.016$ ) and well-differentiated tumours ( $p=0.001$ ); VEGF-C with colon cancers ( $p=0.037$ ), exophytic ( $p=0.048$ ), moderately-differentiated ( $p=0.007$ ) and T3/T4 ( $p=0.010$ ) tumours; VEGFR-2 with invasive adenocarcinoma ( $p=0.007$ ) and VEGFR-3 with the presence of hepatic metastasis ( $p=0.032$ ). Overall survival curves for CRC were statistically significant for rectal cancer, VEGF-C expression and stage III ( $p=0.019$ ) and VEGFR-3 expression and stage IV ( $p=0.047$ ). *Conclusion:* Quantification of VEGF-A, VEGF-C, VEGFR-2 and VEGFR-3 expression seems to provide valuable prognostic information in CRC and the correlation with clinicopathological data revealed an association with characteristics that contribute to progression, invasion and metastasis leading to poorer survival rates and prognosis.

*Abbreviations:* CRC: Colorectal cancer; VEGF: vascular endothelial growth factor; TMA: tissue microarray; NAE: normal adjacent epithelium.

*Correspondence to:* Adhemar Longatto Filho, M.Sc., Ph.D., PMIAC. Life and Health Sciences Research Institute, School of Health Sciences, University of Minho, 4710-057 Braga, Portugal. Tel: +351 253604827, Fax: +351 253604847, e-mail: longatto@ecsau.de.uminho.pt

*Key Words:* Colorectal cancer, vascular endothelial growth factor, clinical and pathological data.

Colorectal cancer (CRC) is the third most common type of cancer (1-4) and the fourth most frequent cause of cancer death (1-5). Globally, CRC incidence varies widely, with higher rates in North America, Australia and western Europe, and the lowest rates in developing countries (4, 6), although in recent years, increasing CRC rates have been reported in these countries (4, 7). According to the World Health Organization (WHO), CRC is one of the most prevalent diseases of the occident world (4, 8) and the second most common cause of death from malignant diseases in Western countries (4, 9, 10). Despite improvements in treatment,

Table I. Detailed aspects of the immunohistochemical procedure used to visualize the different proteins.

Protein marker	Antigen retrieval	Peroxidase inactivation	Detection system	Antibody		
				Company	Dilution	Incubation period
VEGF-A	EDTA buffer 1× pH=8.0	3% H <sub>2</sub> O <sub>2</sub> in methanol, 10 min.	LabVision	Abcam Cambridge, Cambridgeshire, UK	1:100	Overnight, 4°C
VEGF-C	EDTA buffer 1× pH=8.0	3% H <sub>2</sub> O <sub>2</sub> in methanol, 10 min.	LabVision	Invitrogen Carlsbad, California, US	1:200	Overnight, 4°C
VEGF-R2	Citrate buffer 0.01 M pH=6.0	3% H <sub>2</sub> O <sub>2</sub> in methanol, 10 min.	LabVision	Abcam Cambridge, Cambridgeshire, UK	1:200	Overnight, 4°C
VEGF-R3	Citrate buffer 0.01 M pH=6.0	3% H <sub>2</sub> O <sub>2</sub> in methanol, 10 min.	LabVision	Abcam Cambridge, Cambridgeshire, UK	1:100	Overnight, 4°C

mortality remains high, with metastatic spread to the liver occurring in approximately 50% of patients (10). In Portugal, data from Statistics Portugal revealed that CRC is the second most common type of cancer, after gastric cancer, with an incidence of 5,000 individuals year and one of the main causes of death from neoplastic disease (11).

Angiogenesis plays a key role in tumorigenesis and metastatic processes (1, 12, 13). It consists of the formation of new blood vessels from the endothelium of pre-existing vasculature (2, 13). Tumour angiogenesis is essential for neoplastic mass development, favouring access to the blood components and also strengthening the vascular routes in the metastatic process (14-16). Neovascularisation as a whole, promotes tumour growth by supplying nutrients, oxygen and releasing growth factors that promote tumour cell proliferation (13, 14, 17-19).

Numerous studies have demonstrated that tumour overexpression of vascular endothelial growth factor (VEGF) is associated with advanced tumour stage or tumour invasiveness in various types of common human cancer (13, 20-22), and its overexpression in colonic cancer tissue indicates poor prognosis (22); although paradoxically, some data showed that VEGF has no significant prognostic value in colon cancer tissue (23). VEGF-A is the most widely studied angiogenic factor; it increases vascular permeability and is the main angiogenic protein known (4, 12, 19-20, 23-25).

In this study, we evaluated the expression of VEGF-A, VEGF-C, and their receptors VEGFR-2 and VEGFR-3 in a series of 672 cases and determined their correlation with clinicopathological parameters.

**Materials and Methods**

Data from 672 patients treated in the Braga Hospital, North of Portugal, between January 1<sup>st</sup> 2005 and January 1<sup>st</sup> 2010 with CRC diagnosis and submitted to surgical treatment was collected prospectively. The data collected from clinical and preoperative diagnostic examinations included: age, gender, clinical presentation,

Table II. Pattern of protein staining in tumour versus normal adjacent epithelium (NA<sup>E</sup>). \*Examined for statistical significance using the Fisher's exact test (when n<5).

Protein marker	Immunoreaction		
	n	Positive (%)	p-Value
VEGF-A			
NA <sup>E</sup>	132	130 (98.5%)	1.000*
Tumour	500	490 (98.0%)	
VEGF-C			
NA <sup>E</sup>	138	115 (83.3%)	<b>0.004</b>
Tumour	508	466 (91.7%)	
VEGFR-2			
NA <sup>E</sup>	142	133 (93.7%)	0.064
Tumour	501	486 (97.0%)	
VEGFR-3			
NA <sup>E</sup>	139	34 (24.5%)	0.903
Tumour	505	121 (24.0%)	

oncologic history, tumour localization, histological type, macroscopic appearance and preoperative staging. The tumour localization was recorded and classified as colon and rectum (between anal verge and 15 cm at rigid rectoscopy). Operative reports made by surgeons included data such as the presence of perforation; information about tumour mobility and type of surgery was also collected. Histopathological reports included: tumour extent (T), extent of spread to the lymph nodes (N), presence of distant metastasis (M), tumour differentiation, resection margins involvement and lymphatic and blood vessel invasion. The level of positive lymph nodes was not described in all specimens. The histological type of CRC was determined by two experienced pathologists and tumour staging was graded according to the TNM Classification of Malignant Tumours (TNM), sixth edition (25).

A series of formalin-fixed, paraffin-embedded tissues from these patients was analyzed by immunohistochemistry for VEGF-A, VEGF-C, VEGFR-2 and VEGFR-3 expression. Slides from all 672 specimens were reviewed and mapped and tissue microarrays were built using a manual tissue arrayer (MTA-1 Beecher

Table III. Assessment of associations between expression of VEGF-A and VEGF-C and the receptors VEGFR-2 and VEGFR-3 in tumour cases.

	VEGFR-2			VEGFR-3		
	n	Positive n (%)	p-Value	n	Positive n (%)	p-Value
VEGF-A-positive	464	453 (97.6%)	1.000	471	120 (25.5%)	0.210
VEGF-C-positive	446	434 (97.3%)	1.000	451	117 (25.9%)	<b>0.047</b>

Table IV. Assessment of correlation between VEGF-A, VEGF-C, VEGFR-2 and VEGFR-3 expression and clinical data. \*Examined for statistical significance using Fisher's exact test (when n&lt;5).

Protein marker	VEGF-A			VEGF-C			VEGFR-2			VEGFR-3		
	n	Positive (%)	p-Value	n	Positive (%)	p-Value	n	Positive (%)	p-Value	n	Positive (%)	p-Value
Gender												
Male	304	99.3	0.016*	309	91.6	0.446	306	97.1	0.776*	307	24.4	0.731
Female	181	96.1		184	93.5		179	97.8		182	25.8	
Age, years												
≤71.5	242	97.9	1.000*	249	90.4	0.107	244	97.1	0.802	247	23.9	0.565
>71.5	242	98.3		229	94.2		240	97.5		241	26.1	
Personal history-polyps												
Negative	419	98.3	0.352*	427	92.0	0.804*	420	97.4	0.689*	423	25.8	0.289
Positive	66	97.0		66	93.9		65	96.9		66	19.7	
CRC												
Negative	472	98.3	0.219*	480	92.3	1.000*	472	97.2	1.000*	476	25.2	0.533*
Positive	13	92.3		13	92.3		13	100.0		13	15.4	
Cancer												
Negative	446	98.2	0.533*	454	91.6	0.060	447	97.1	0.612*	450	25.6	0.292
Positive	39	97.4		39	100.0		38	100.0		39	17.9	

Instrument, Silver Spring, MD, USA). Representative areas of the CRC lesions were selected and cores of 1.0 mm in diameter were twice-sampled and arranged at 0.3 mm from each other in the recipient paraffin block. A database was built for every block produced, including the coordinates of each core and case of origin. Comparison of expression in tumour *versus* normal cells was also possible since, in most cases, the same paraffin section contained both neoplastic and normal colonic epithelium. VEGF immunohistochemical expression was correlated with the available clinicopathological data. All cases in this study were identified using a series of unified codes, for the following review. The study protocol was approved by the Ethics Committee of the Braga Hospital.

**Immunohistochemistry.** Tissue microarray (TMA) protein expression was evaluated by immunohistochemistry. Briefly, after deparaffinization and rehydration, 3 µm sections were immersed in 0.01 M citrate buffer (pH 6.0) and heated at 98°C for 20 min for epitope antigen retrieval. Subsequently, endogenous peroxidase was blocked with 0.3% hydrogen peroxide in methanol. The primary antibody incubation step take place overnight at 4°C. Visualization was developed with 3,3'-diaminobenzidine (DAKO Corporation, Carpinteria, CA, USA) and counterstaining with Harris's haematoxylin (Merck, Darmstadt, Germany). Negative controls were

obtained by omitting the primary antibody incubation step and tonsils were used as positive control.

Details of the procedure used for each antibody are found in Table I. After the immunohistochemical procedure, the slides were evaluated and then photographed under a microscope.

**Immunohistochemical evaluation.** Sections were scored semi-quantitatively for the extent of immunoreaction as follows: 0: 0% of immunoreactive cells; 1: <5% of immunoreactive cells; 2: 5-50% of immunoreactive cells; and 3: >50% of immunoreactive cells. The intensity of staining was scored semi-qualitatively as 0: negative; 1: weak; 2: intermediate; and 3: strong. The final score for the immunoreaction was defined as the sum of both parameters (extent and intensity), and grouped as negative, 0, weak, 2, moderate, 3, and strong, 4/6. For statistical purposes, only the moderate and strong immunoreaction final scores were considered as positive. Evaluation of VEGF immunohistochemical expression was performed blindly by two independent observers and discordant cases were discussed under a double-head microscope in order to determine a final score.

**Statistical analysis.** All data were collected and stored in an Excel PC database and statistically analyzed using the Statistical Package for the Social Sciences, version 19.0 (SPSS Inc., Chicago, IL,



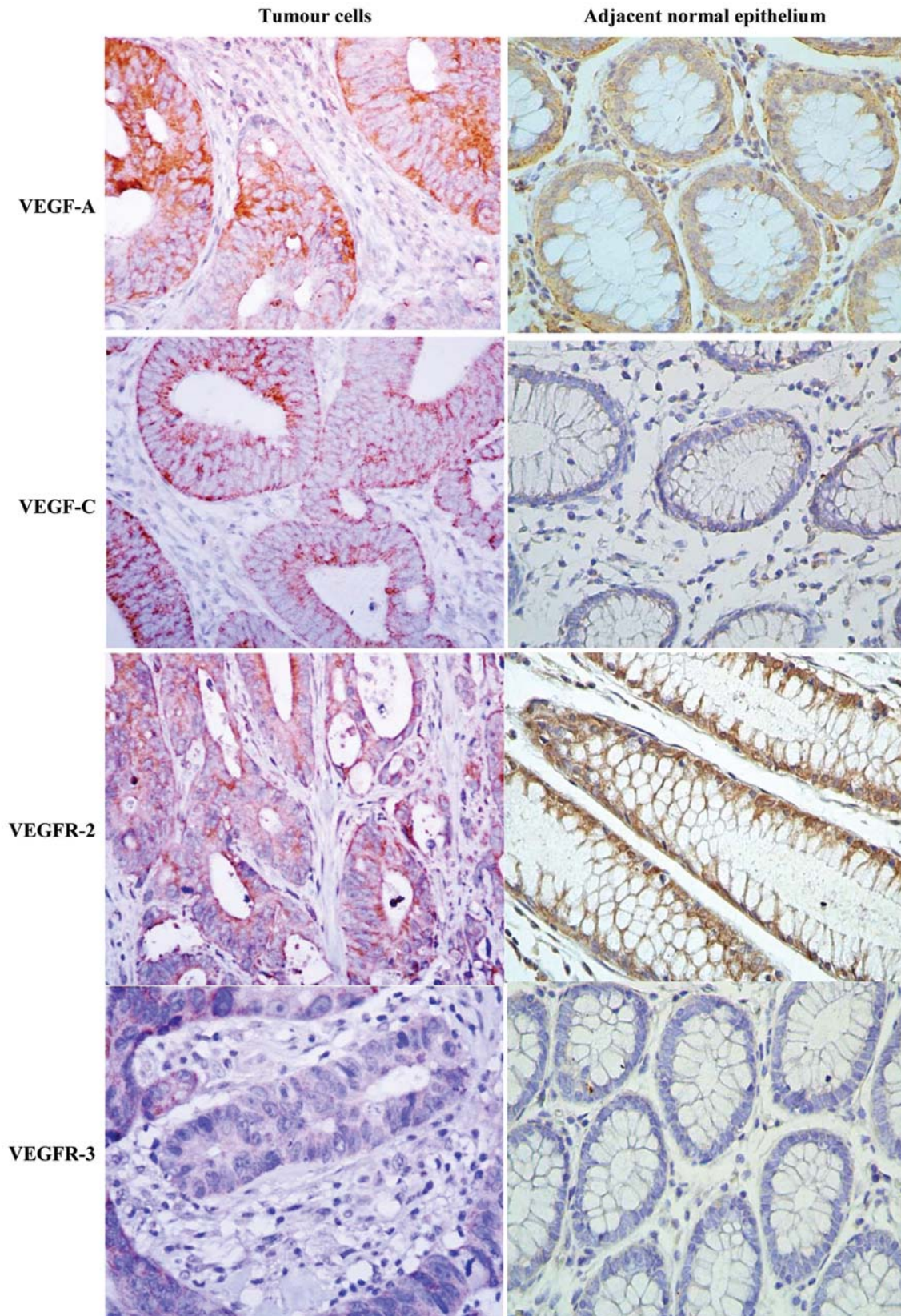


Figure 1. Immunohistochemical expression of VEGF-A, VEGF-C, VEGF-R2 and VEGF-R3 in colorectal cancer samples (original magnification  $\times 40$ ).

Table V. Assessment of correlation between VEGF-A, VEGF-C, VEGFR-2 and VEGFR-3 expression and diagnostic/surgical data. \*Examined for statistical significance using Fisher's exact test (when  $n < 5$ ).

Protein marker	VEGF-A			VEGF-C			VEGFR-2			VEGFR-3		
	n	Positive (%)	p-Value	n	Positive (%)	p-Value	n	Positive (%)	p-Value	n	Positive (%)	p-Value
Presentation												
Asymptomatic	87	96.6	0.207*	89	88.8	0.168	87	97.7	1.000*	88	23.9	0.795
Symptomatic	398	98.5		404	93.1		398	97.2		401	25.2	
Rectal examination												
Mobile tumour	40	97.5	1.000*	42	81.0	0.300*	40	90.0	1.000*	40	25.0	0.339*
Fixed tumour	25	100.0		25	92.0		25	92.0		24	12.5	
Localization												
Colon	352	98.3	0.711*	357	93.8	0.037	354	98.0	0.115	358	24.6	0.756
Rectum	133	97.7		136	88.2		131	95.4		131	26.0	
Macroscopic appearance												
Polypoid	244	98.0	0.896	255	89.8	0.048	246	98.0	0.278	252	25.4	0.439
Ulcerative	112	97.4		115	94.8		115	98.3		114	25.4	
Infiltrative	38	97.4		39	94.9		40	97.5		38	13.2	
Exophytic	38	100.0		37	97.4		35	92.1		39	28.2	
Villous	2	100.0		1	50.0		2	100.0		2	50.0	
CEA (ng/ml)												
>5	314	94.9	1.000*	314	90.1	0.869	314	93.9	0.756	313	24.6	0.779
≥5	78	93.6		78	89.7		78	94.9		78	23.1	
Hepatic metastasis												
Absent	443	98.2	0.535*	450	92.2	1.000*	443	97.1	0.613*	445	23.8	0.032
Present	39	97.4		40	92.5		39	100		41	39.0	
Tumour mobility												
Mobile	418	97.8	0.240	426	91.8	0.158	419	97.4	0.786	423	24.6	0.630
Fixed	63	100.0		63	96.8		62	96.8		62	27.4	
Tumour perforation												
Absent	460	98.0	0.480	468	92.3	1.000*	461	97.6	0.079	464	24.6	0.403
Present	25	100.0		25	92.0		24	91.7		25	32.0	

USA). All comparisons were examined for statistical significance using Pearson's chi-square ( $\chi^2$ ) test and the Fisher's exact test (when  $n < 5$ ), with the threshold for significant  $p$ -values of less than 0.05. Survival curves were determined for overall survival by the Kaplan–Meier method.

## Results

*VEGF-A, VEGF-C, VEGFR-2 and VEGFR-3 expressions in CRC samples.* A total of 672 samples were organized into TMAs, including tumour and normal adjacent epithelium (NA<sup>E</sup>). Sections were evaluated for immunoeexpression and the obtained results are given in Table II, which summarizes the frequency of VEGF-A, VEGF-C, VEGFR-2 and VEGFR-3 expression in tumour cells and NA<sup>E</sup>.

When analyzing the results of Table II, it can be seen that only VEGF-C is overexpressed in tumours when tumour cells and NA<sup>E</sup> are compared ( $p=0.004$ ), and VEGFR-2 shows a tendency to be differently expressed ( $p=0.064$ ).

Figure 1 shows representative cases of positive staining for VEGF-A, VEGF-C, VEGFR-2 and VEGFR-3 in tumour cells and in NA<sup>E</sup>.

*Associations between VEGF-A, VEGF-C and VEGFR-2, VEGFR-3 expression in CRC tissues.* We analyzed the associations between the expression of VEGF-A, VEGF-C and the receptors VEGFR-2 and VEGFR-3 in CRC tissues and observed that in the tumour samples, VEGF-C positivity was associated with VEGFR-3 positivity ( $p=0.047$ ) (Table III).

*Associations between VEGF-A, VEGF-C, VEGFR-2 and VEGFR-3 expressions in CRC tissues and clinical data.* An assessment of the correlation between the expression of VEGF-A, VEGF-C, VEGFR-2 and VEGFR-3 and the clinical data revealed that VEGF-A-positive cases were less frequently associated with female gender ( $p=0.016$ ) and VEGF-C had a tendency to be associated with a personal history of CRC ( $p=0.060$ ) Table IV.

When analyzing the correlation with data from diagnosis/surgery, we found an association between VEGF-C expression and tumour localized in colon ( $p=0.037$ ) and an exophytic macroscopic cancer appearance ( $p=0.048$ ). VEGFR-3 shows an association with the presence of hepatic metastasis' ( $p=0.032$ ) Table V.

Table VI. Assessment of correlation between expression of VEGF-A, VEGF-C, VEGF-R2 and VEGF-R3 pathological data. \*Examined for statistical significance using Fisher's exact test (when n<5).

Protein marker	VEGF-A			VEGF-C			VEGFR-2			VEGFR-3		
	n	Positive (%)	p-Value	n	Positive (%)	p-Value	n	Positive (%)	p-Value	n	Positive (%)	p-Value
Tumor size												
≤4.5 cm	281	97.5	0.161*	281	94.3	0.088	276	98.2	0.291	277	27.1	0.287
>4.5 cm	175	99.4		181	90.1		178	96.6		181	22.7	
Histological type												
Adenocarcinoma	403	98.3	0.869	408	92.6	0.470	404	98.0	0.007	403	26.1	0.214
Mucinous	50	98.0		52	90.4		49	93.9		53	15.1	
Invasive	25	96.0		25	96.0		24	100.0		25	28.0	
Signet ring & mucinous	3	100.0		4	75.0		4	75.0		4	0.0	
Differentiation												
Well	209	99.0	0.001	215	92.6	0.007	210	97.1	0.973	212	23.6	0.474
Moderate	208	97.6		208	94.2		205	97.6		206	27.7	
Poor	48	97.9		48	89.6		47	97.9		49	22.4	
Undifferentiated	2	66.7		4	50.0		4	100.0		4	0.0	
Tumour penetration												
Tis	5	100.0	0.476	5	80.0	0.010	4	100.0	0.939	5	20.0	0.830
T1/T2	87	96.6		88	85.2		87	97.7		85	27.1	
T3/T4	387	98.4		394	94.2		388	97.4		393	24.2	
Spread to lymph nodes												
Absent	277	97.8	0.742*	276	92.4	0.767	273	97.4	0.782*	273	24.2	0.696
Present	194	98.5		203	93.1		198	97.0		202	25.7	
Vessel invasion												
Absent	166	98.2	0.889	166	92.2	0.988	163	97.5	0.747	164	23.2	0.578
Present	301	98.0		308	92.2		303	97.0		306	25.5	
TNM stage												
0	1	100.0	0.713	1	100.0	0.336	1	100.0	0.940	1	0.0	0.550
I	76	96.1		76	86.8		75	98.7		74	28.4	
II	183	98.4		181	94.5		180	97.2		180	21.7	
III	147	98.6		156	92.3		150	96.7		154	24.7	
IV	70	98.6		71	93.0		70	97.1		72	30.6	

When analysing the correlation with pathological data, we found an association between the expression of VEGF-A and well-differentiated tumours ( $p=0.001$ ); VEGF-C and moderately-differentiated ( $p=0.007$ ) and T3/T4 penetration tumours ( $p=0.010$ ); VEGFR-2 expression and invasive adenocarcinoma ( $p=0.007$ ) Table VI.

Overall survival curves according to expression of VEGF-A, VEGF-C, VEGFR-2 and VEGFR-3. A statistically significant association between VEGF-C expression and stage III rectal cancer ( $p=0.019$ ) and VEGFR-3 expression and stage IV rectal cancer ( $p=0.047$ ) was found Figures 2-7.

## Discussion

Our results corroborate the premise that angiogenesis plays a key role in tumourigenesis and metastatic processes (1, 12, 13), because all the markers involved in neovascularization were consistently expressed in tumour cells. Additionally,

VEGF-C, a lymphangiogenic marker was significantly over-expressed in cancer cells rather than in normal counterparts. This general view of our results clearly indicates that CRCs are predominantly composed of cancer cells that are directly or indirectly associated with the high expression of molecules related to blood neovascularization (angiogenesis) and that the major lymphangiogenic molecules are also importantly expressed in cancer cells.

Normally, the VEGF family is weakly-expressed in a wide variety of human and animal tissues; however, high levels of VEGF expression can be detected at sites where physiological angiogenesis is required, such as foetal tissue or placenta and in a vast majority of human tumours and some other diseases e.g. chronic inflammatory disorders, diabetes mellitus, and ischemic heart disease (4). Furthermore, both the VEGF family and its receptors are expressed at high levels in metastatic human colon carcinomas and in tumour-associated endothelial cells, respectively (4, 20). Consequently, VEGF is recognized as a prominent angiogenic factor in colon



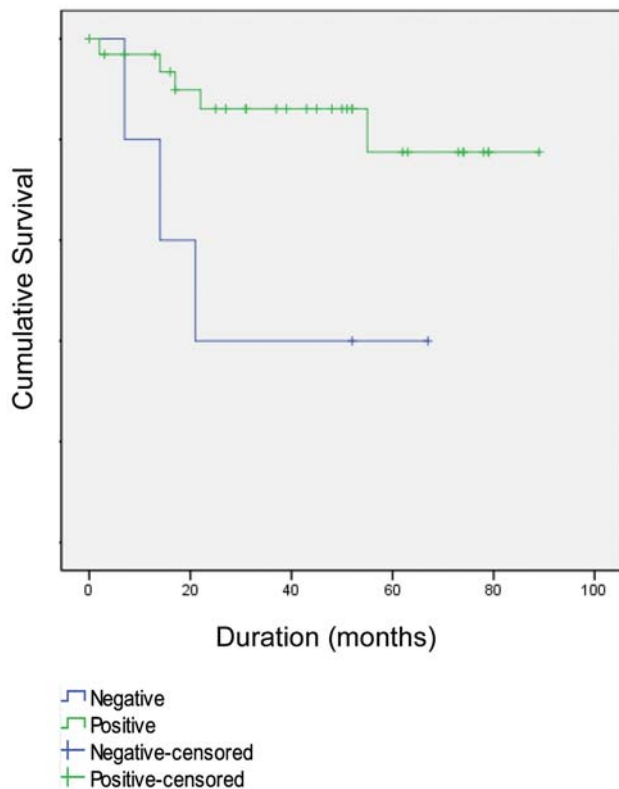


Figure 2. Survival curve of patients with stage III rectal cancer according to VEGF-C expression, assessed by the log-rank test ( $p=0.019$ ).

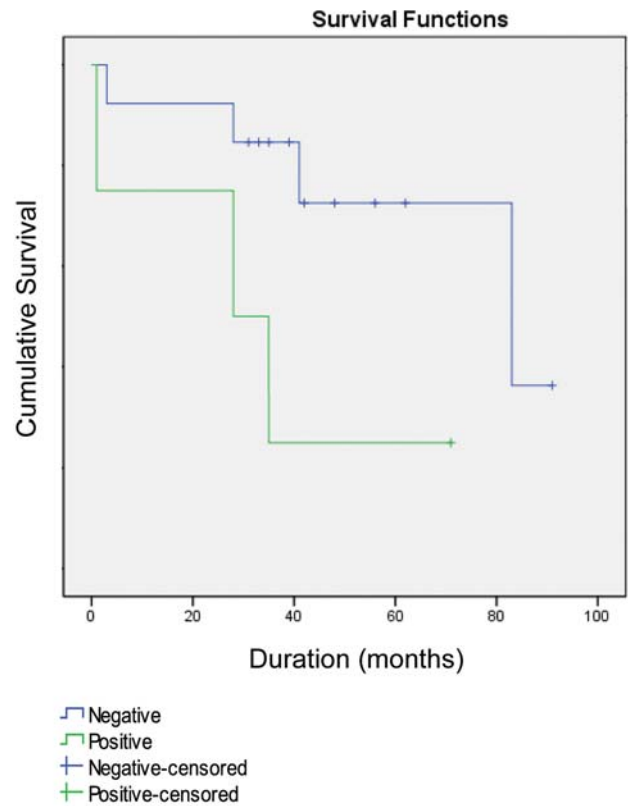


Figure 3. Survival curve of patients with stage IV rectal cancer according to VEGFR-3 expression, assessed by the log-rank test ( $p=0.047$ ).

carcinoma and the assessment of VEGF expression may be useful in predicting metastasis from CRC (4, 20). In fact, VEGF-A expression was found to be higher in patients with metastatic tumours than in those with non-metastatic tumours (4, 20, 26), and high levels of VEGF-A expression were associated with advanced cancer stage and related to an unfavourable prognosis (4, 22, 23, 27). Other studies have shown that VEGF-A is also a useful marker for prognosis by significantly correlating with angio-lymphatic invasion, lymph node status and depth of invasion, although it was not an independent prognostic factor (4, 14, 24).

The effect of VEGF depends not only on tumour cell expression of VEGF, but also on that of VEGF-R in the endothelial cells (4, 13). The ligands of the VEGF family include VEGF-A, VEGF-B, VEGF-C, VEGF-D and VEGF-E; and the receptors are VEGFR-1, -2 and -3 (4, 28).

In literature, the role of the VEGF family members in CRC has, to date, mainly concentrated on VEGF-A, but the newer members of the family, VEGF-C and VEGF-D, may have important roles to play in both angiogenesis and lymphangiogenesis (29).

VEGF-A promotes angiogenesis through enhancement of permeability, activation, survival, migration, invasion, and proliferation of endothelial cells (4, 30). VEGF-A plays a role in early tumour development at the stage of adenoma formation (4, 10, 31) and some studies documented an overexpression of VEGF-A in CRC (4, 24).

The *VEGF-C* gene was also found to be poorly expressed, with only moderate overexpression in CRCs compared to control tissues (29, 32); however, the number of samples studied was very small ( $n=12$ ). In a larger series of patients, the immunohistochemical expression of VEGF-C was correlated with lymph node spread (29, 33). In our study, contrary to what is found in literature, we did not observe a statistically positive relation between VEGF-A expression in tumours and  $NA^E$ . We observed that VEGF-C is overexpressed in tumours when comparing tumour cells with  $NA^E$  ( $p=0.004$ ), and VEGFR-2 shows a tendency for a similar association ( $p=0.064$ ).

We also analyzed the associations between expression of VEGF-A, VEGF-C and the receptors VEGFR-2 and VEGFR-3 in CRC tissues and observed that in tumour samples, VEGF-C positivity was associated with VEGFR-3

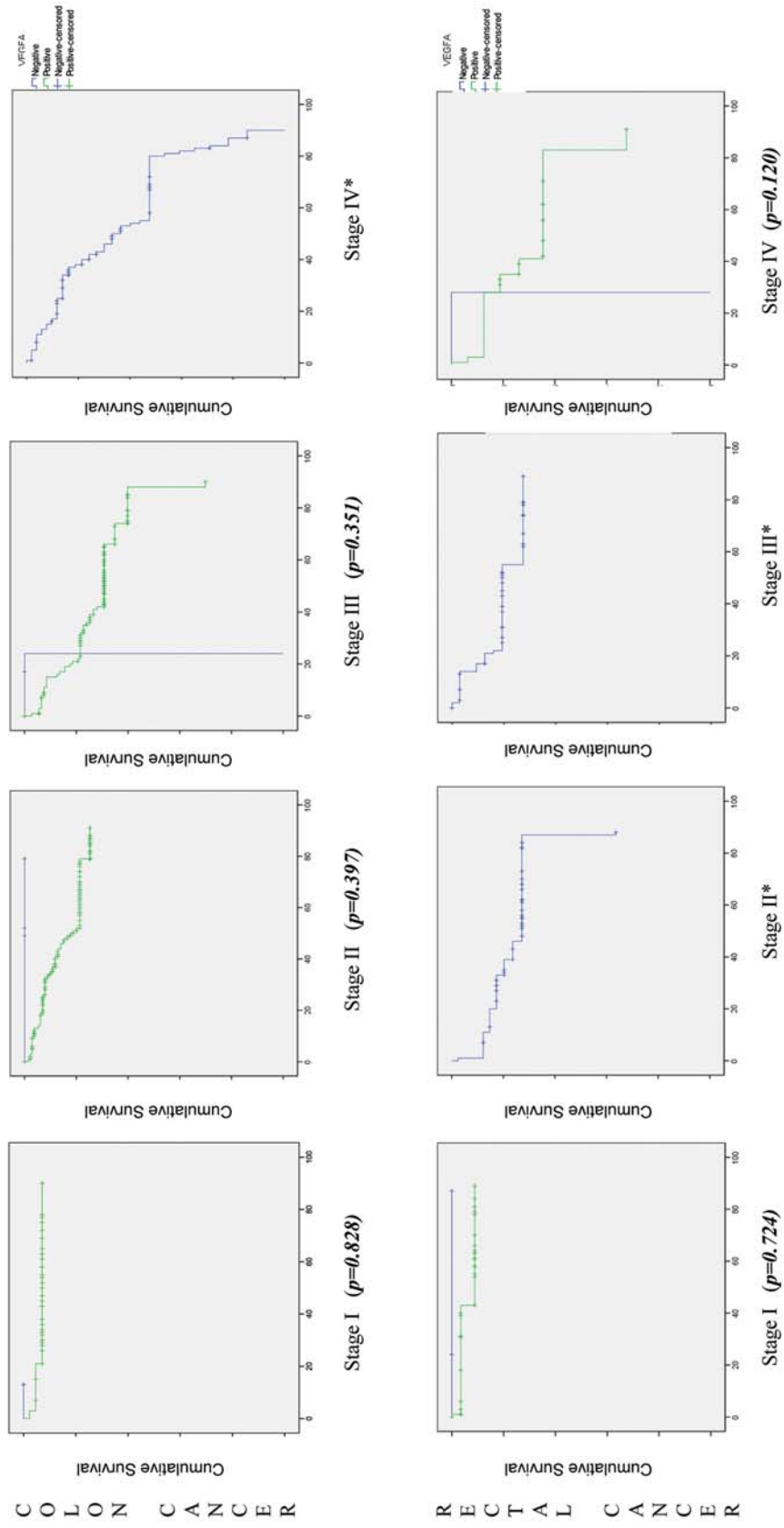


Figure 4. Survival curve of patients with different stages of colorectal cancer according to VEGF-A expression, assessed by log-rank test. \*No comparison was possible, because all cases were VEGF-A-positive.



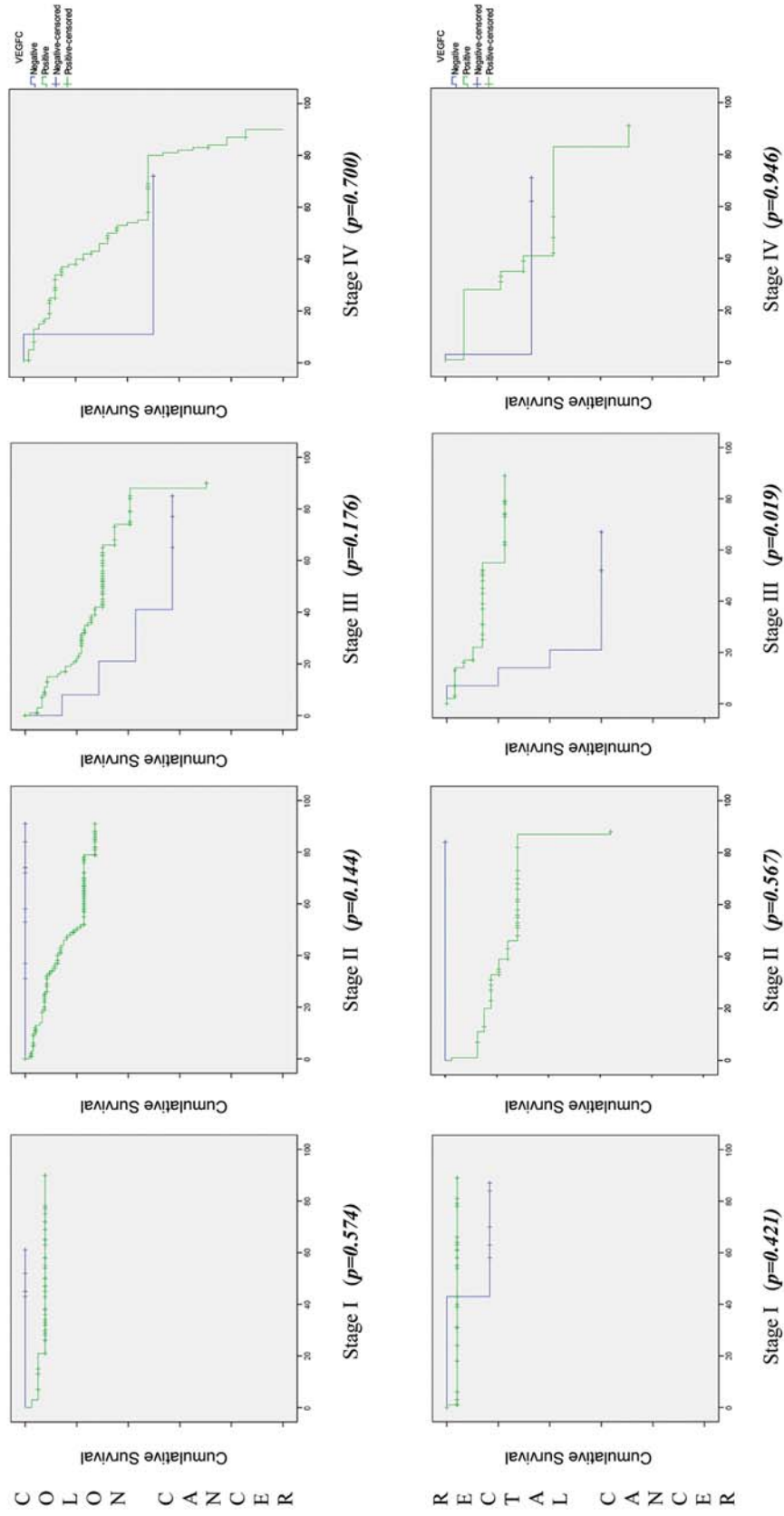


Figure 5. Survival curve of patients with different stages of colorectal cancer according to VEGF-C expression, assessed by the log-rank test.

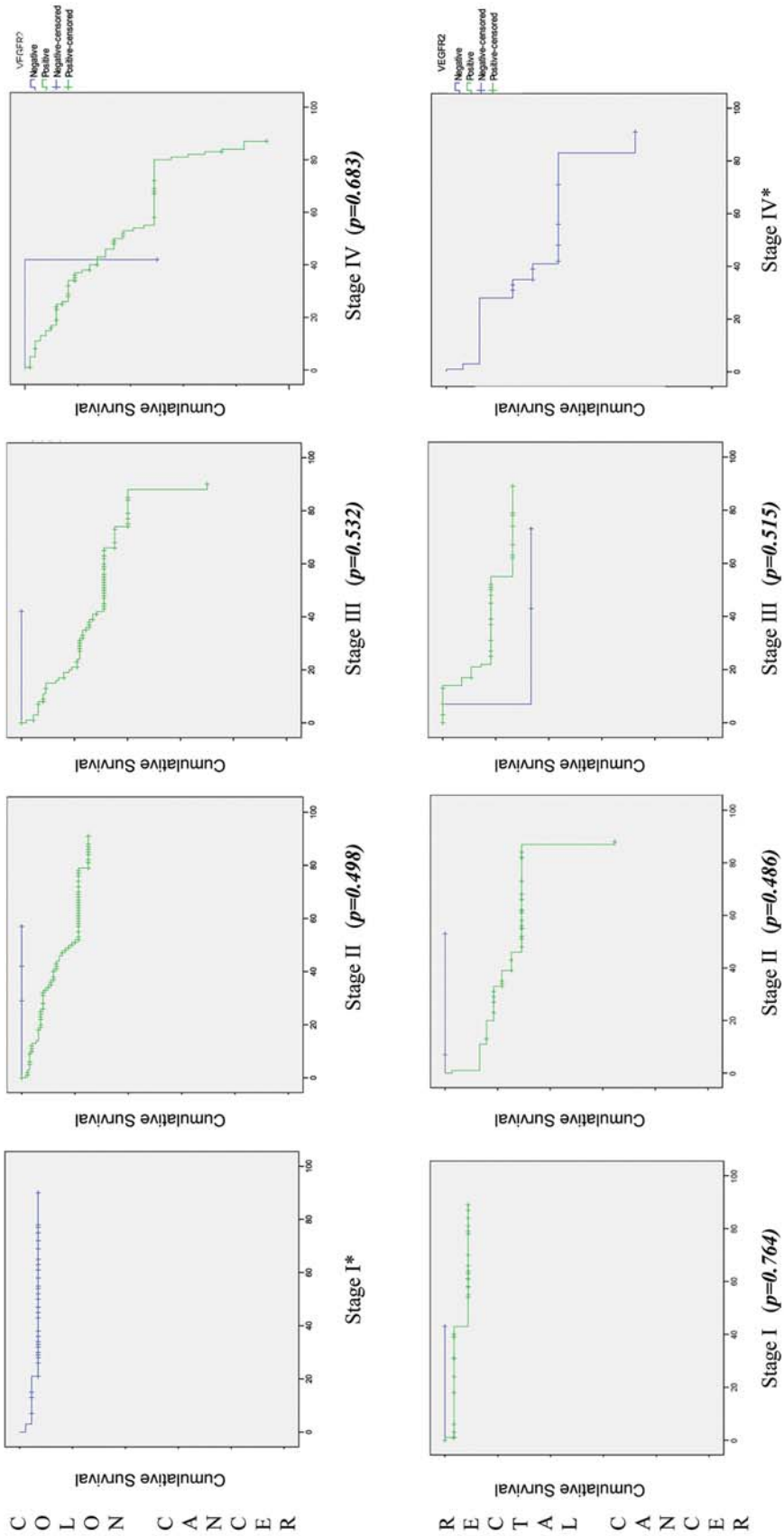


Figure 6. Survival curve of patients with different stages of colorectal cancer according to VEGFR-2 expression, assessed by log-rank test. \*No comparison was possible, because all cases were VEGFR-2-positive.

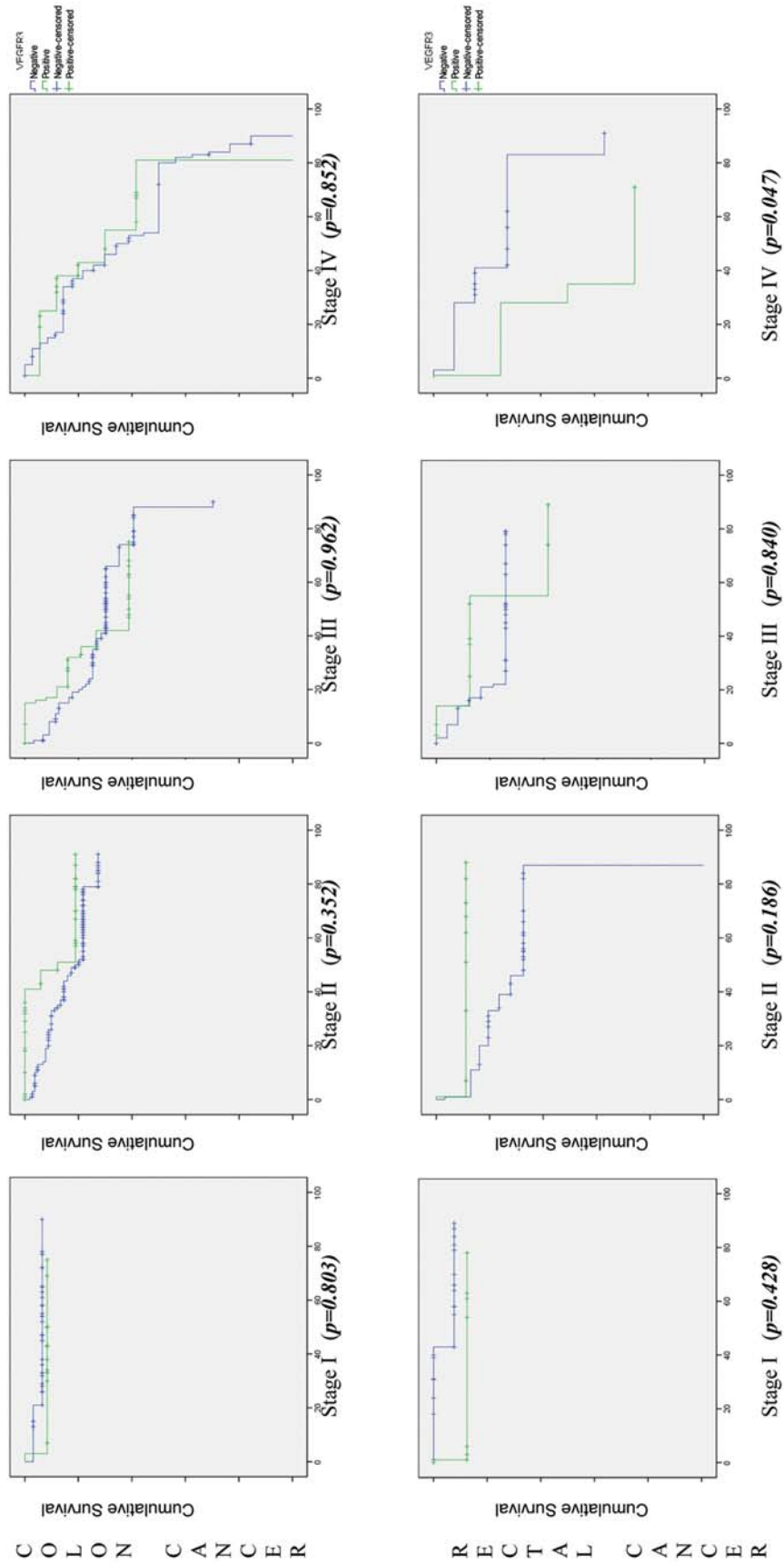


Figure 7 . Survival curve of patients with different stages of colorectal cancer according to VEGFR-3 expression, assessed by the log-rank test.

expression ( $p=0.047$ ); this is consistent with the results mentioned above, where lymphangiogenesis induced by VEGF-C is driven mainly by the activation of the tyrosine kinase-linked receptor VEGFR-3 (34). This receptor occurs in embryonic vascular endothelial cells, where its production decreases during development and is subsequently restricted to lymphatic vessels after vascular net formation (35). Many experimental studies have indicated that VEGFR-3 and its ligands (VEGF-C and -D) stimulate lymphangiogenesis in tumours and induce proliferation and growth of new lymphatic capillaries, enhancing the incidence of lymph node metastasis (36-40).

The comparison of VEGF-A, VEGF-C, VEGFR-2 and VEGFR-3 expressions and the clinicopathological data, data from diagnosis/surgery and pathological data revealed that VEGF-A-positive cases were associated with male gender ( $p=0.016$ ) and well-differentiated tumours ( $p=0.001$ ); VEGF-C expression with cancers localized in colon ( $p=0.037$ ), exophytic ( $p=0.048$ ), moderately-differentiated ( $p=0.007$ ) and T3/T4 penetrating tumours ( $p=0.010$ ); VEGFR-2 shows an association with invasive adenocarcinoma ( $p=0.007$ ) and VEGFR-3 with the presence of hepatic metastasis ( $p=0.032$ ). All of these characteristics contribute to progression, invasion and metastasis, and poorer survival and prognosis, as stated in literature to be associated with VEGF-A overexpression in CRC (4, 30). Moreover VEGF-C overexpression in CRC has been found to correlate with lymphatic invasion and lymph node metastasis (41). Increased *VEGF-C* mRNA expression in tumour tissues was also documented to be positively correlated with lymphatic metastasis and poor prognosis (42). In our series, we reported significantly poor survival when we correlated overall survival with VEGF-C in stage III rectal cancer ( $p=0.019$ ) and VEGFR-3 expression in stage IV ( $p=0.047$ ).

### Competing Interests

We declare no financial or non-financial competing interests.

### References

- 1 Svagzdys S, Lesauskaite V, Pavalkis, D, Nedzelskienė I, Pranys D and Tamelis A: Microvessel density as new prognostic marker after radiotherapy in rectal cancer. *BMC Cancer* 9(1): 95, 2009.
- 2 Des Guetz G, Uzzan B, Nicolas P, Cucherat M, Morere JF, Benamouzig R, Breau JL and Perret G-Y: Microvessel density and VEGF expression are prognostic factors in colorectal cancer. Meta-analysis of the literature. *Br J Cancer* 94: 1823-1832, 2006.
- 3 Brenner H, Hoffmeister M and Hauq U: Should colorectal cancer screening start at the same age in European countries? Contributions from descriptive epidemiology. *Br J Cancer* 99: 532-535, 2008.
- 4 Martins SF, Reis RM, Rodrigues AM, Baltazar F and Longatto A: Role of endoglin and VEGF family expression in colorectal cancer prognosis and anti-angiogenic therapies. *WJC* 10(2): 272-280, 2011.
- 5 Parkin DM, Bray F, Ferlay J and Pisani P: Estimating the world cancer burden: Globocan 2000. *Int J Cancer* 94: 153-156, 2001.
- 6 Abdulrahman MA: Clinico-Pathological Patterns of Colorectal Cancer in Saudi Arabia: Younger with advanced stage presentation. *Saudi J Gastroenterol* 13: 84-87, 2007.
- 7 Center MM, Jemal A, Smith RA and Ward E: Worldwide variations in colorectal cancer. *CA Cancer J Clin* 59: 366-378, 2009.
- 8 Pereira A: *Surgery, Pathology and Clinics* 47: 678-700, 1999.
- 9 Henry AK, Niu X and Boscoe FP: Geographic disparities in colorectal cancer survival. *Inter J of Health Geogr* 8(48), 2009.
- 10 Barozzi C, Ravaioli M, D'Errico A, Grazi GL, Poggioli G, Cavrini G, Mazziotti A and Grigioni WF: Relevance of Biologic Markers in Colorectal Carcinoma – A comparative study of a broad panel. *Cancer* 94: 647-657, 2002.
- 11 Chaves FC: Rastreio e Prevenção dos tumores malignos do aparelho digestivo. *Permanyer Portugal*, 2005, Carlos Nobre Leitão, Inc. 2005.
- 12 Graziano F and Cascinu S: Prognostic molecular markers for planning adjuvant chemotherapy trials in Dukes' B colorectal cancer patients: How much evidence is enough? *Ann Oncol* 14: 1026-1038, 2003.
- 13 Pang, RW and Poon R: Clinical implications of angiogenesis in cancers. *Vasc Health Risk Manag* 2: 97-108, 2006.
- 14 Saad RS, Liu YL, Nathan G, Celebrezze J, Medich D and Silverman JF: Endoglin (CD105) and vascular endothelial growth factor as prognostic markers in colorectal cancer. *Mod Pathol* 17: 197-203, 2004.
- 15 Cressey R, Wattananupong O, Lertprasertsuke N and Vinitketkumnuen U: Alteration of protein expression pattern of vascular endothelial growth factor (VEGF) from soluble to cell-associated isoform during tumourigenesis. *BMC Cancer* 5(128), 2005.
- 16 Kitadai Y: Angiogenesis and lymphangiogenesis of gastric cancer. *Journal of Oncology*, vol. 2010, Article ID 468725, 8 pages, 2010. doi:10.1155/2010/468725.
- 17 Kwon KA, Kim SH, Oh SY, Lee S, Han JY, Kim KH, Goh RY, Choi HJ, Park KJ, Roh MS, Kim HJ, Kwon HC and Lee JH: Clinical significance of preoperative serum vascular endothelial growth factor, interleukin-6, and C-reactive protein level in colorectal cancer. *BMC Cancer* 10(203), 2010.
- 18 Tanigawa N, Amaya H, Matsumura M, Lu C, Kitaoka, Matsuyama K and Ryusuke M: Tumor angiogenesis and mode of metastasis in patients with colorectal cancer. *Cancer Res* 57: 1043-1046, 1997.
- 19 Mosch B, Reissenweber B, Neuber C and Pietzsch J: Eph receptors and ephrin ligands: important players in angiogenesis and tumor angiogenesis. *J Oncol*. Article ID 135285, 12 pages, 2010. doi:10.1155/2010/135285.
- 20 De Vita F, Orditura M, Lieto E, Infusino S, Morgillo F, Martinelli E, Castellano P, Romano C, Ciardiello F, Catalano G, Pignatelli C and Galizia G: Elevated perioperative serum vascular endothelial growth factor levels in patients with colon carcinoma. *Cancer* 100: 270-278, 2004.
- 21 Lee SJ, Kim JG, Sohn SK, Chae YS, Moon JH, Kim SN, Bae HI, Chung HY and Yu W: No association of vascular endothelial growth factor-A (VEGF-A) and VEGF-C expression with survival in patients with gastric cancer. *Cancer Res Treat* 41: 218- 223, 2009.



- 22 Liang JF, Wang HK, Xiao H, Li N, Cheng CX, Zhao YZ, Ma YB, Gao JZ, Bai RB and Zheng HX: Relationship and prognostic significance of SPARC and VEGF protein expression in colon cancer. *J Exp Clin Cancer Res* 29(7), 2010.
- 23 Zheng S, Han MY, Xiao ZX, Peng JP and Dong Q: Clinical significance of vascular endothelial growth factor expression and neovascularization in colorectal carcinoma. *World J Gastroenterol* 9: 1227-1230, 2003.
- 24 Myśliwiec P, Pawlak K, Kukliński A and Kedra B: Combined perioperative plasma endoglin and VEGF – Assessment in colorectal cancer patients. *Folia Histochem Cytobiol* 47: 231-236, 2009.
- 25 Greene FL, Page DL, Balch CM, Fleming ID and Fritz AG: *AJCC Cancer Staging Manual* (Sixth ed.). Springer-Verlag Inc. 2002. New York.
- 26 Cascinu S, Staccioli MP, Gasparini G, Giordani P, Catalano V, Ghiselli R, Rossi C, Baldelli AM, Graziano F, Saba V, Muretto P and Catalano G: Expression of vascular endothelial growth factor can predict event-free survival in stage II colon cancer. *Clin Cancer Res* 6: 2803-2807, 2000.
- 27 Cao D, Hou M, Guan YS, Jiang M and Gou HF: Expression of HIF-1 $\alpha$  and VEGF in colorectal cancer: Association with clinical outcomes and prognostic implications. *BMC Cancer* 9(432), 2009.
- 28 Duhoux FP and Machiels JP: Antivascular therapy for epithelial ovarian cancer. *J Oncol Article ID 372547*, 16 pages, 2010. doi:10.1155/2010/372547.
- 29 George ML, Tutton MG, Janssen F, Arnaout A, Abulafi M, Eccles S and Swift RI: VEGF-A, VEGF-C, and VEGF-D in colorectal cancer progression. *Neoplasia* 3: 420-427, 2001.
- 30 Hanrahan V, Currie MJ, Gunningham SP, Morrin HR, Scott PA, Robinson BA and Fox SB: The angiogenic switch for vascular endothelial growth factor (VEGF)-A, VEGF-B, VEGF-C, and VEGF-D in the adenoma carcinoma sequence during colorectal cancer progression. *J Pathol* 200: 183-194, 2003.
- 31 Miyazaki T, Okada N, Ishibashi K, Ogata K, Ohsawa T, Ishiguro T, Nakada H, Yokoyama M, Matsuki M, Kato H, Kuwano H and Ishida H: Clinical significance of plasma level of vascular endothelial growth factor-C in patients with colorectal cancer. *Jpn J Clin Oncol* 38: 839-839, 2008.
- 32 Andre T, Kotelevets L, Vaillant JC, Coudray AM, Weber L PS, Parc R, Gispach C and Chastre E: VEGF, VEGF-B, VEGF-C and their receptors KDR, FLT-1 and FLT-4 during the neoplastic progression of human colonic mucosa. *Int J Cancer* 86: 174-181, 1986.
- 33 Akagi K, Ikeda Y, Miyazaki M, Abe T, Kinoshita J, Maehara Y and Sugimachi K: Vascular endothelial growth factor-C (VEGF-C) expression in human colorectal cancer tissues. *Br J Cancer* 83: 887-891, 2000.
- 34 Saharinen P, Tammela T, Karkkainen MJ and Alitalo K: Lymphatic vasculature: Development, molecular regulation and role in tumor metastasis and inflammation. *Trends Immunol* 25: 387-395, 2004.
- 35 Kaipainen A, Korhonen J, Mustonen T, van Hinsbergh VW, Fang GH, Dumont D, Breitman M and Alitalo K: Expression of the *fms*-like tyrosine kinase 4 gene becomes restricted to lymphatic endothelium during development. *Proc Natl Acad Sci USA* 92: 3566-3570, 1995.
- 36 Karpanen T, Egeblad M, Karkkainen MJ, Kubo H, Ylä-Herttuala S, Jäättelä M and Alitalo K: Vascular endothelial growth factor C promotes tumor lymphangiogenesis and intralymphatic tumor growth. *Cancer Res* 61: 1786-1790, 2001.
- 37 Mattila MM, Ruohola JK, Karpanen T, Jackson DG, Alitalo K and Härkönen PL: VEGF-C induced lymphangiogenesis is associated with lymph node metastasis in orthotopic MCF-7 tumors. *Int J Cancer* 98, 2002.
- 38 Stacker SA, Caesar C, Baldwin ME, Thornton GE, Williams RA, Prevo R, Jackson DG, Nishikawa S, Kubo H and Achen MG: VEGF-D promotes the metastatic spread of tumor cells via the lymphatics. *Nat Med* 7: 151-152, 2001.
- 39 Skobe M, Hawighorst T, Jackson DG, Prevo R, Janes L, Velasco P, Riccardi L, Alitalo K, Claffey K and Detmar M: Induction of tumor lymphangiogenesis by VEGF-C promotes breast cancer metastasis. *Nat Med* 7: 192-198, 2001.
- 40 Lui Z, Ma Q, Wang X and Zhang Y: Inhibiting tumor growth of colorectal cancer by blocking the expression of vascular endothelial growth factor receptor 3 using interference vector-based RNA interference. *Int J Mol Med* 25: 59-64, 2010.
- 41 He M, Cheng Y, Li W, Liu Q, Liu J, Huang J and Fu X: Vascular endothelial growth factor C promotes cervical cancer metastasis via up-regulation and activation of RhoA/ROCK-2/moesin cascade. *BMC Cancer* 10(170), 2010.
- 42 Thiele W and Sleeman J: Tumor-induced lymphangiogenesis: a target for cancer therapy? *J Biotechnol* 124: 224-241, 2006.

*Received February 11, 2013*

*Revised March 6, 2013*

*Accepted March 6, 2013*