

# Retropubic, laparoscopic and mini-laparoscopic radical prostatectomy: a prospective assessment of patient scar satisfaction

Carmelo Quattrone · Antonio Cicione · Carlos Oliveira · Riccardo Autorino · Francesco Cantiello · Vincenzo Mirone · Marco De Sio · Luca Carrubbo · Rocco Damiano · Carlo Pavone · Estevão Lima

Received: 18 June 2014 / Accepted: 19 October 2014  
© Springer-Verlag Berlin Heidelberg 2014

## Abstract

**Purpose** To compare patient scar satisfaction after retro-pubic, standard laparoscopic, mini-laparoscopic (ML) and open radical prostatectomy (RP).

**Methods** Patients undergoing RP for a diagnosis of localized prostate cancer at a single academic hospital between September 2012 and December 2013 were enrolled in this prospective nonrandomized study. The patients were included in three study arms: open surgery, VLP and ML. A skin stapler was used for surgical wound closure in all cases. Demographic and main surgical outcomes, including perioperative complications, were analyzed. Surgical scar satisfaction was measured using the Patient and Observer Scar Assessment Questionnaire (POSAS) and the two Body

Image Questionnaire (BIQ) scales, respectively, recorded at skin clips removal and either at 6 months after surgery.

**Results** Overall, 32 patients were enrolled and completed the 6 month of follow-up. At clips removal, laparoscopic approaches offered better scar result than open surgery according to the POSAS. However, at 6 months, no differences were detected between VLP and open, whereas ML was still associated with a better scar outcome ( $p = 0.001$ ). This finding was also confirmed by both BIQ scales, including the body image score (ML  $9.8 \pm 1.69$ , open  $15.73 \pm 3.47$ , VLP  $13.27 \pm 3.64$ ;  $p = 0.001$ ) and the cosmetic score (ML  $16.6 \pm 4.12$ , open  $10 \pm 1.9$ , LP  $12.91 \pm 3.59$ ;  $p = 0.001$ ). Small sample size and lack of randomization represent the main limitations of this study.

**Conclusions** ML RP offers a better cosmetic outcome when compared to both open and standard laparoscopic RP, representing a step toward minimal surgical scar. The impact of scar outcome on RP patients' quality of life remains to be determined.

**Keywords** Mini-laparoscopy · Radical prostatectomy · POSAS · Surgical scar

C. Quattrone · C. Pavone  
Department of Urology, University of Palermo, Palermo, Italy

A. Cicione · F. Cantiello · R. Damiano  
Department of Urology, Magna Graecia University, Catanzaro, Italy

C. Oliveira · E. Lima  
Department of Urology, Braga Hospital, Braga, Portugal

R. Autorino · M. De Sio  
Urology Unit, Second University of Naples, Naples, Italy

R. Autorino (✉)  
Urology Institute, University Hospitals, Case Western Reserve University, Cleveland, OH, USA  
e-mail: ricautor@gmail.com

V. Mirone  
Department of Urology, Federico II University, Naples, Italy

L. Carrubbo  
Department of Economy and Law, University of Cassino and Southern Lazio, Cassino, Italy

## Introduction

Radical prostatectomy (RP) represents the standard surgical treatment for patients with low- and intermediate-risk localized PCa and a life expectancy >10 years [1]. Open RP has represented the gold standard technique for over 30 years, and it is still routinely performed [2]. The laparoscopic [3] and, more recently, the robot-assisted approach [4] have been largely adopted with the aim of reducing surgical morbidity.

Over the last 5 years, the field of urologic surgery has witnessed an increasing interest toward *scarless* techniques, with the ultimate aim of further lowering surgical morbidity and expediting postoperative recovery. Based on this concept, novel surgical approaches such as natural orifice transluminal endoscopic surgery (NOTES) and laparo-endoscopic single-site surgery (LESS) have been explored [5]. However, these techniques carry some limitations, including an unfavorable ergonomics and the lack of optimal instrumentation, are still under development.

On the other hand, mini-laparoscopy (ML), which was initially conceived in the early 90 s maintaining the key principles of standard laparoscopy (i.e., triangulation), has been rediscovered thanks to the recent availability of more reliable instrumentation [6]. In terms of surgical scarring, the use of trocars of smaller diameter, not requiring formal skin closure, could potentially translate into less pain. A broad range of common urological procedures have safely and effectively performed with this newly re-discovered technique, mostly for kidney diseases [7]. Porpiglia et al. recently showed a better patients scar satisfaction using ML instruments to carry out laparoscopic pyeloplasty [8].

Despite the large number of studies comparing oncological and functional outcomes between the different surgical approaches [9, 10], available literature on objective scar assessment of patients undergoing RP remains anecdotal [11].

The aim of present study was to analyze the cosmetic result of ML RP compared with open and standard laparoscopic approaches.

## Patients and methods

### Study design

This is a prospective nonrandomized study carried out in a tertiary care institution (Braga Hospital, Braga, Portugal) between September 2012 and December 2013. The study was conducted in accordance with good clinical practice guidelines and the Declaration of Helsinki, and the local institutional review board approved the protocol. All subjects gave written informed consent before enrollment in the study. Patients were allocated in 3 study groups according to surgeon preference: open surgery, standard laparoscopy and ML.

### Patients

Eligible patients had a diagnosis of localized prostate cancer with a PSA level  $\leq 10$  ng/ml, biopsy Gleason score  $\leq 7$ , age  $\leq 70$  years, trans-rectal ultrasound prostate volume estimated  $\leq 50$  cc, life expectative  $\geq 10$  years and American

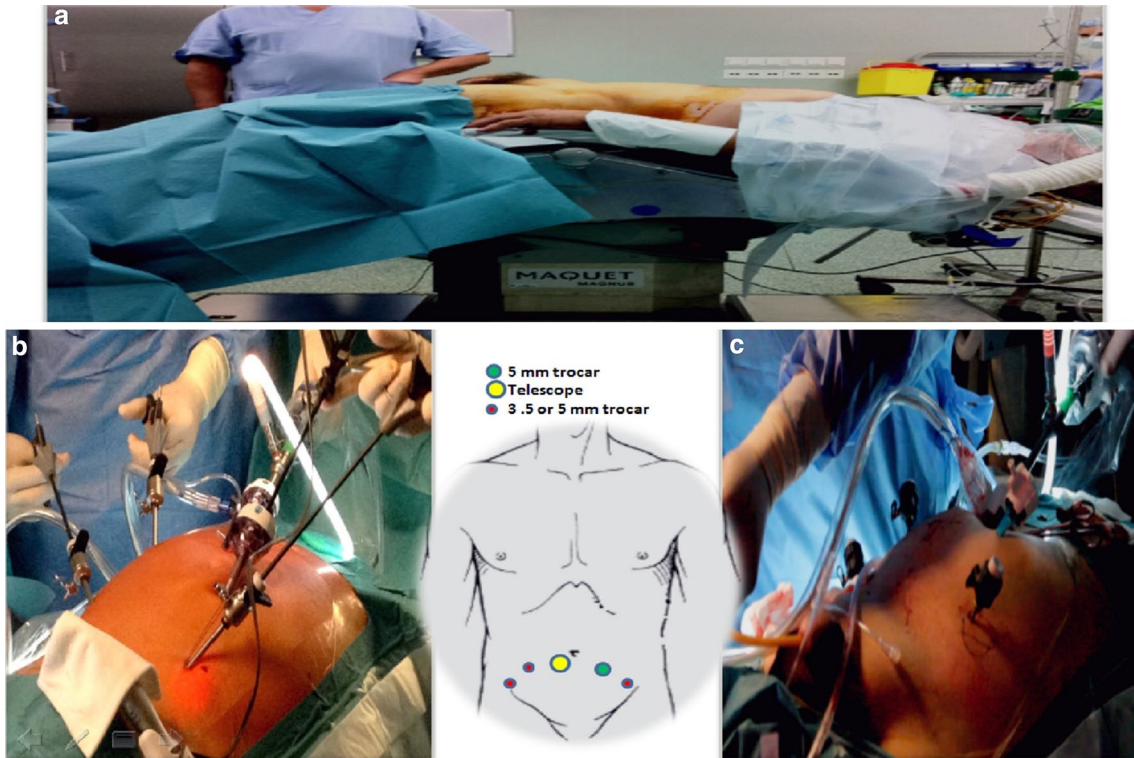
Society of Anesthesiology score (ASA score)  $\leq 2$ . Exclusion criteria were previous pelvic surgery or trans-urethral resection of the prostate (TURP), diabetes mellitus, chronic use of corticosteroid medication.

### Surgical techniques

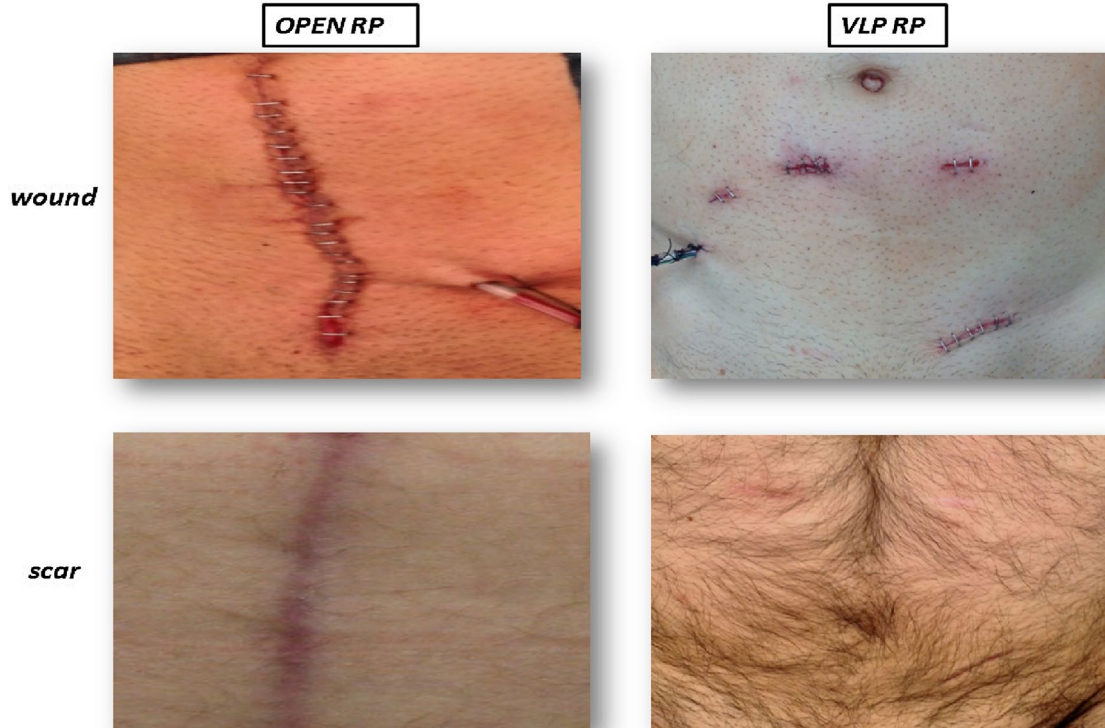
All procedures were performed by a senior surgeon with extensive laparoscopic experience (E.L.). For the open approach, a standard retropubic technique through an infra-umbilical midline incision was used [12]. For both laparoscopic and ML approaches, the same surgical technique was adopted [13]. A limited pelvic lymphadenectomy was selectively performed in high-risk (Gleason score  $>6$ ) patients. In brief, the patient was placed in Trendelenburg supine position (Fig. 1). A 10-mm skin incision was made laterally to umbilical scar in order to create a preperitoneal space by introducing a dissecting balloon trocar. After that, the balloon trocar was replaced by a 12-mm optical trocar. Two 3.5-mm trocars (5 mm in case of standard laparoscopy) were positioned medially to the anterior superior iliac spine, bilaterally. One 5-mm trocar was placed approximately 3 fingerbreadths medially to the left anterior superior iliac spine while another 3.5-mm (5 mm in case of standard laparoscopy) trocar in the right para-rectal line, between the optical trocar and the previously placed right 3.5-mm trocar. In all procedures, sterile skin closure clips were used and removed at postoperative day 7 (Fig. 2). Protocol for pain management was the same for all patients regardless the technique. Patients received intravenous ketorolac for 48 h. In addition, tramadol was given “on demand” for severe pain.

### Outcomes

Baseline demographic, surgical outcomes, intra (graded according to Satava) [14]- and postoperative complications (graded according to Clavien–Dindo) [14]), and pathology findings were recorded. Biochemical recurrence was defined according to current guidelines as single PSA  $>0.2$  ng/ml followed by a subsequent rise. Functional outcomes related to continence (number of pads per day) and erectile function (IIEF score) were recorded. Scar evaluation and patient scar satisfaction represented the primary outcomes. The first one was performed at time of clips removal and at 6 month after surgery. At both times, a validated assessment tool, the Patient and Observer Scar Assessment Questionnaire (POSAS), was used [15, 16]). This consists of two scales with six items rating 1–10 where the highest score reflects the worst finding. The observer items were collected by an “observer” (a physician part of the research team). Patient scar satisfaction was assessed using the Body Image Questionnaire (BIQ) [17] at



**Fig. 1** Patient position (a) and trocar placement for standard laparoscopy (b) and mini-laparoscopic (c) radical prostatectomy



**Fig. 2** Surgical wound and scar at 6 months after open or laparoscopic approaches

**Table 1** Demographics

	Open (n = 11)	VLP (n = 10)	ML (n = 11)	p value
Age, years	63.2 ± 3.4	67.1 ± 2.9	64.4 ± 4.8	ns
BMI, kg/m <sup>2</sup>	25.1 ± 2.1	23.6 ± 1.2	24.7 ± 0.9	ns
ASA score				
1	8 (72.7)	8 (80)	9 (81.8)	ns
2	3 (27.3)	2 (20)	2 (18.2)	
Prostate volume, cc	37.1 ± 8.3	38.3 ± 5.4	44.5 ± 2.3	ns
PSA, ng/dl	6.05 ± 2.7	5.89 ± 1.6	5.65 ± 1.7	ns
Biopsy Gleason score				
Score 6	7 (63.6)	9 (90)	9 (81.8)	ns
Score 7	4 (36.4)	1 (10)	2 (18.2)	
Baseline erectile function <sup>^</sup>				
IIEF score	21.1 (2.7)	21.2 (2.9)	20.9 (2.8)	ns
No/mild ED	11 (100)	10 (100)	11 (100)	
Moderate/severe ED	0 (0)	0 (0)	0 (0)	

Values expressed as mean ± (SD) or n (%)

ns = nonsignificant ( $p > 0.05$ ) for all pairwise comparisons

VLP video laparoscopy, ML mini-laparoscopy, BMI body mass index, PSA prostate specific antigen, ED erectile dysfunction

<sup>^</sup> Based on IIEF (International Index Erectile Function): 22–25: no erectile dysfunction; 17–21: mild erectile dysfunction; 12–16: mild-to-moderate erectile dysfunction; 8–11: moderate erectile dysfunction; 5–7: severe erectile dysfunction

6 months after surgery. This is composed of two spheres: five questions about operation impact on body image (overall range 5-low to 20-high impact) and three questions about satisfaction on scar appearance (overall range 3-very unsatisfied to 24-very satisfied). A common postoperative protocol in terms of analgesia was employed. A visual analog pain score (VAPS) at postoperative day 1 and at time of discharge was used to measure surgical pain.

### Statistical analysis

The statistical significance of differences in means and proportions was tested with one-way ANOVA test followed by Bonferroni post hoc test and the Pearson  $\chi^2$  test, respectively. Statistical significance was set at  $p < 0.05$ . All data were analyzed using Statistical Package for Social Sciences (SPSS) 17.0 for Windows.

### Results

Overall, 32 patients were enrolled and completed the 6-month follow-up. Eleven patients underwent to open RP, ten to standard laparoscopic RP, and eleven to ML RP. No

significant differences were detected between the groups in terms of baseline demographics (Table 1).

Surgical outcomes, pathology findings and functional outcomes are summarized in Table 2. Only one (9 %) Satava grade 1 intraoperative complication occurred during a ML RP. Postoperative complications were mostly Clavien grade 1. On pathology, the disease was mostly organ-confined low-grade cancer and negative surgical margins. No patient developed biochemical recurrence at 6 months after surgery. There was no difference in terms of 6-month functional outcomes between groups.

Table 3 summarizes analgesic use, pain assessment, scar evaluation and patient scar satisfaction. Both laparoscopic approaches reported a lower VAPS than open surgery at postoperative day 1 ( $p = 0.01$ ) and at patients discharge ( $p = 0.006$ ). Moreover, a lower (nonstatistically significant) use of in-hospital “on-demand” tramadol was recorded for minimally invasive techniques compared to open ( $p = 0.1$ ). Scar assessment was deemed to be better at clips removal for laparoscopic approaches compared to open, by the observer ( $p = 0.001$ ) and the patient ( $p = 0.001$ ). At 6 months, according to the observer assessment, standard laparoscopy and mini-laparoscopy were still both better than open ( $p = 0.001$ ), whereas ML performed better than standard lap and open according to the patient ( $p = 0.001$ ).

This finding was also confirmed by BIQ assessment at 6 months when patients in the ML group scored higher than those of open and standard laparoscopy group for both body image score ( $p = 0.001$ ) and cosmetic score ( $p = 0.001$ ).

### Discussion

Assessment of surgical scars represents a challenging task as both patient-related factors, such as age and concomitant disease, and tissue-related features (blood supply, infection) affect healing of surgical wounds. Thus, investigators are still making several attempts to devise a reliable and valid scar assessment scale in a broad range of scar types [15].

The use of smaller laparoscopic instruments (i.e., mini-laparoscopy) has been recently rediscovered with the purpose to minimize patient morbidity and obtain a *scarless* surgery preserving the principles of standard laparoscopy, above all instrument triangulation. A variety of urological procedures have been successfully performed using ML, including pyeloplasty, radical nephrectomy, radical prostatectomy and adrenalectomy [7].

For most patients contemplating urological surgery, cosmesis is of less concern than surgeon reputation and avoidance of surgical complications [18]. The aim of the present study was to compare three currently available surgical

**Table 2** Surgical outcomes, pathology findings and functional outcomes

	Open ( <i>n</i> = 11)	VLP ( <i>n</i> = 10)	ML ( <i>n</i> = 11)	<i>p</i> value
<i>Surgical outcomes</i>				
Operative time, min	110.30 ± 18.50	124.60 ± 15.70	118.69 ± 25.20	ns
Hospital stay, days	4.02 ± 1.50	3.89 ± 1.23	3.79 ± 1.51	ns
Intraop. complications				
Satava grade 1	0	0	1 (9)	ns
Satava grade 2	0	0	0	
Postop. complications				
Clavien grade 1	2 (18.1)	1 (10)	1 (9)	ns
Clavien grade 2	0	0	0	
Time to catheter removal, days	10 ± 2.51	10 ± 1.31	10 ± 1.50	ns
<i>Pathology findings</i>				
pStage				
T2b	1 (9)	2 (20)	1 (9)	ns
T2c	9 (82)	8 (80)	9 (82)	
T3a	1 (9)	0	1 (9)	
Gleason score				
6	7 (63.3)	7 (70)	8 (72.7)	ns
7	4 (36.4)	3 (30)	3 (27.3)	
Positive surgical margins	3 (27.2)	2 (20)	2 (18.2)	ns
<i>12-month functional outcomes</i>				
Continence				
0–1 pad	8 (91)	9 (90)	11 (100)	ns
≥2 pads	1 (9)	1 (10)	0 (0)	
Erectile function <sup>^</sup>				
IIEF score	12.9 (3.1)	14.5 (2.6)	14.2 (3.1)	ns
No/mild ED	7 (64)	9 (90)	9 (82)	
Moderate/severe ED	4 (36)	1 (10)	2 (18)	

Values expressed as mean ± (SD) or *n* (%)

ns = nonsignificant (*p* > 0.05) for all pairwise comparison

Intraoperative complications: Satava grade 1 = substitution of a 3 mm with a 5-mm trocar; Satava grade 2 = conversion to open. Postoperative complications: Clavien Grade 1 = fever

VLP video laparoscopy, ML mini-laparoscopy, ED erectile dysfunction, GS Gleason score

<sup>^</sup> Based on IIEF (International Index Erectile Function): 22–25: no erectile dysfunction; 17–21: mild erectile dysfunction; 12–16: mild-to-moderate erectile dysfunction; 8–11: moderate erectile dysfunction; 5–7: severe erectile dysfunction

**Table 3** Analgesic use, pain assessment and cosmetic outcomes in the three study groups

	Open ( <i>n</i> = 11)	Standard VLP ( <i>n</i> = 10)	ML ( <i>n</i> = 11)	<i>p</i> value
Use of “on-demand” tramadol, mg	40 ± (51)	9 ± (30)	9 ± (30)	ns
VAPS				
Postop. day 1	2.82 ± 0.75	2.02 ± 0.89*	1.72 ± 0.82*	0.01*
Discharge	2.09 ± 0.7	1.18 ± 0.87*	0.90 ± 0.88*	0.006*
POSAS at clips removal				
Observer	18.36 ± 3.44	10.64 ± 4.03	8.4 ± 2.22	0.001*
Patient	23.64 ± 6.19	15.91 ± 4.85	10.5 ± 3.24	0.001*
POSAS at 6 months				
Observer	14.73 ± 3.50	9.09 ± 3.48	7.5 ± 8.10	0.001*
Patient	18.01 ± 4.92	14.64 ± 3.17	8.10 ± 2.23	0.001 <sup>^</sup>
BIQ at 6 months				
Body image score	15.73 ± 3.47	13.27 ± 3.64	9.8 ± 1.69	0.001 <sup>^</sup>
Cosmetic score	10 ± 1.9	12.91 ± 3.59	16.6 ± 4.12	0.001 <sup>^</sup>

Values expressed as mean ± SD

ns = nonsignificant (*p* > 0.05) for all pairwise comparisons

VAPS visual analog pain score, POSAS Patient and Observer Scar Assessment Questionnaire, BIQ Body Image Questionnaire, ML mini-laparoscopy, VLP video laparoscopy

\* *p* significant for pairwise comparison between ML-Open and standard VLP-Open (nonsignificant for other comparisons)

<sup>^</sup> *p* significant for pairwise comparison between ML-Open and ML-VLP (nonsignificant for other comparisons)

approaches for RP in terms of surgical scars and their perception by the patients. With the recent interest in *scarless* techniques in urology, this comparative assessment can be regarded as an attempt to better understand how patients undergoing this procedure perceive the impact of surgical scars on their body image. Bucher reported as patients are usually fascinated by new surgical approaches in particular when surgical risk is similar to traditional approach and a scar-free surgery may be achieved [19].

Interestingly, our findings suggest that at time of suture removal (7 days after surgery in the present study), both patient and physician have a better perception of scar related to laparoscopic approaches compared to those related to open surgery. However, at 6 months after surgery, this finding is only confirmed by physician while from a patient's point of view standard laparoscopy and open approach perform similarly, with only mini-laparoscopy holding a better scar assessment. These findings might be explained by fact that scarring is a time-dependent process [20] and cosmetic satisfaction may be fluid [21].

Delongchamps et al. [11] also found no significant difference neither in patient's scar satisfaction nor in scar-related impact on quality of life between open and standard laparoscopic RP at 3 months postoperatively. In particular, using a nonvalidated questionnaire to compute the impact of scar on quality of life (where "0" as no impact and "10" as the highest impact), the median reported values were 0 and 1, respectively, for patients underwent to open and laparoscopic RP.

In a recent review on public perception of *scarless* surgery, Autorino et al. [5] showed that safety and efficacy are as the primary surgical outcomes for patients while scar issue is such significant just when equivalence results and risks are assured. In a prospective comparative study, Porpiglia et al. showed that patients who underwent mini-laparoscopic pyeloplasty were significantly more satisfied with their cosmetic result than those who had standard laparoscopic approach [8]. To note, this finding was also obtained using the POSAS Questionnaire. A better cosmetic outcome using smaller trocar has also been reported in general surgery literature thought comparative studies on standard laparoscopic cholecystectomy [22, 23]. Matching these findings with ours and those ones of Delongchamps [11], one can speculate that cosmetic result is a secondary concern for patient undergone to oncological surgery and it should be considered as primary just when oncological and functional outcomes are comparable.

A common postoperative analgesia protocol was used for all study groups. A lower use of "on-demand" analgesics was recorded for VLP and ML compared to open, without reaching a statistical significance. There were no differences in terms of VAPS between the two laparoscopic approaches. A recent systematic review looking at this same parameter in patients undergoing cholecystectomy

concluded that ML seems to provide a lower degree of pain when compared to standard laparoscopy [24]. This may be explained by the fact that our ML–RP was not a "pure" 3-mm surgery. This is due to the drawbacks of currently available 3 mm instrumentation, such as the absence of 3 mm Hem-o-lok applicator and the low resolution of 3 mm telescope.

Some study limitations should be recognized. The sample size in each of the study arms is limited. As this was conceived as an exploratory study, a formal sample size calculation was not performed. However, the prospective study design, despite the lack of randomization, represents a notable study feature. The short length of follow-up and the lack of quality of life assessment can also be regarded as major limitations. More robust analysis has been already performed by others about surgical, functional and oncological outcomes for different radical prostatectomy approaches [9, 10, 25]. The lack of a quality of life assessment does not allow determining how the cosmetic result impact this in oncological patients.

Despite these limitations, to the best of our best knowledge, this represents the first prospective study assessing these three approaches for RP using validated assessment tools (i.e., POSAS, BIQ, VAPS) and our results indicate that ML approach might offer a better surgical scar from the patient's point of view. Thus, further studies are warranted in this field.

## Conclusions

ML can be regarded as an emerging minimally invasive surgical option in patients undergoing RP. Findings from the present prospective study suggest that ML can offer a better cosmetic outcome when compared to both open and standard laparoscopy, representing a significant step toward minimal surgical scar and less surgical pain. How these factors impact the overall quality of life of this patient population remains to be addressed.

**Conflict of interest** The authors declare that they have no conflict of interest.

**Ethical standard** This study was approved by our ethics committee and performed in accordance with the ethical standards laid down in the 1964 Declaration of Helsinki and its later amendments. All persons gave their informed consent prior to their inclusion in the study.

## References

1. Heidenreich A, Bastian PJ, Bellmunt J, Bolla M, Joniau S, van der Kwast T, Mason M, Matveev V, Wiegel T, Zattoni F, Mottet N (2014) EAU guidelines on prostate cancer. part 1: screening,

- diagnosis, and local treatment with curative intent-update 2013. *Eur Urol* 65:124–137
2. Mullins JK, Feng Z, Trock BJ, Epstein JI, Walsh PC, Loeb S (2012) The impact of anatomical radical retropubic prostatectomy on cancer control: the 30-year anniversary. *J Urol* 188:2219–2224
  3. Hruza M, Bermejo JL, Flinspach B, Schulze M, Teber D, Rumpelt HJ, Rassweiler JJ (2013) Long-term oncological outcomes after laparoscopic radical prostatectomy. *BJU Int* 111:271–280
  4. Montorsi F, Wilson TG, Rosen RC, Ahlering TE, Artibani W, Carroll PR, Costello A, Eastham JA, Ficarra V, Guazzoni G, Menon M, Novara G, Patel VR, Stolzenburg JU, Van der Poel H, Van PH, Mottrie A (2012) Best practices in robot-assisted radical prostatectomy: recommendations of the Pasadena Consensus Panel. *Eur Urol* 62:368–381
  5. Autorino R, White WM, Gettman MT, Khalifeh A, De SM, Lima E, Kaouk JH (2012) Public perception of “scarless” surgery: a critical analysis of the literature. *Urology* 80:495–502
  6. Pini G, Rassweiler J (2012) Minilaparoscopy and laparoendoscopic single-site surgery: mini- and single-scar in urology. *Minim Invasive Ther Allied Technol* 21:8–25
  7. Porpiglia F, Autorino R, Cicione A, Pagliarulo V, Falsaperla M, Volpe A et al (2014) Contemporary urologic minilaparoscopy: indications, techniques and surgical outcomes in a multi-institutional European cohort. *J Endourol* 28(8):951–957
  8. Fiori C, Morra I, Bertolo R, Mele F, Chiarissi ML, Porpiglia F (2013) Standard vs mini-laparoscopic pyeloplasty: perioperative outcomes and cosmetic results. *BJU Int* 111:E121–E126
  9. Robertson C, Close A, Fraser C, Gurung T, Jia X, Sharma P, Vale L, Ramsay C, Pickard R (2013) Relative effectiveness of robot-assisted and standard laparoscopic prostatectomy as alternatives to open radical prostatectomy for treatment of localised prostate cancer: a systematic review and mixed treatment comparison meta-analysis. *BJU Int* 112:798–812
  10. Moran PS, O’Neill M, Teljeur C, Flattery M, Murphy LA, Smyth G, Ryan M (2013) Robot-assisted radical prostatectomy compared with open and laparoscopic approaches: a systematic review and meta-analysis. *Int J Urol* 20:312–321
  11. Delongchamps NB, Belas O, Saighi D, Zerbib M, Peyromaure M (2013) Prospective comparison of scar-related satisfaction and quality of life after laparoscopic versus open radical prostatectomy: no differences from patients’ point of view. *World J Urol* 31:389–393
  12. Walsh PC (1998) Anatomic radical prostatectomy: evolution of the surgical technique. *J Urol* 160:2418–2424
  13. Stolzenburg JU, Kallidonis P, Minh D, Dietel A, Hafner T, Dimitriou D, Al-Aown A, Kyriazis I, Liatsikos EN (2009) Endoscopic extraperitoneal radical prostatectomy: evolution of the technique and experience with 2400 cases. *J Endourol* 23:1467–1472
  14. Kazaryan AM, Rosok BI, Edwin B (2013) Morbidity assessment in surgery: refinement proposal based on a concept of perioperative adverse events. *ISRN Surg* 2013:625093
  15. Durani P, McGrouther DA, Ferguson MW (2009) Current scales for assessing human scarring: a review. *J Plast Reconstr Aesthet Surg* 62:713–720
  16. <http://www.posas.org>. Patient and Observer Scar Assessment Scale (2014)
  17. Dunker MS, Stiggelbout AM, van Hogeand RA, Ringers J, Griffioen G, Bemelman WA (1998) Cosmesis and body image after laparoscopic-assisted and open ileocolic resection for Crohn’s disease. *Surg Endosc* 12:1334–1340
  18. Olweny EO, Mir SA, Best SL, Park SK, Donnally IC, Cadeddu JA, Tracy CR (2012) Importance of cosmesis to patients undergoing renal surgery: a comparison of laparoendoscopic single-site (LESS), laparoscopic and open surgery. *BJU Int* 110:268–272
  19. Bucher P, Pugin F, Ostermann S, Ris F, Chilcott M, Morel P (2011) Population perception of surgical safety and body image trauma: a plea for scarless surgery? *Surg Endosc* 25:408–415
  20. Linares HA (1996) From wound to scar. *Burns* 22:339–352
  21. Golkar FC, Ross SB, Sperry S, Vice M, Luberice K, Donn N, Morton C, Hernandez JM, Rosemurgy AS (2012) Patients’ perceptions of laparoendoscopic single-site surgery: the cosmetic effect. *Am J Surg* 204:751–761
  22. Bisgaard T, Klarskov B, Trap R, Kehlet H, Rosenberg J (2002) Microlaparoscopic vs conventional laparoscopic cholecystectomy: a prospective randomized double-blind trial. *Surg Endosc* 16:458–464
  23. Novitsky YW, Kercher KW, Czerniach DR, Kaban GK, Khera S, Gallagher-Dorval KA, Callery MP, Litwin DE, Kelly JJ (2005) Advantages of mini-laparoscopic vs conventional laparoscopic cholecystectomy: results of a prospective randomized trial. *Arch Surg* 140:1178–1183
  24. Gurusamy KS, Samraj K, Ramamoorthy R, Farouk M, Fusai G, Davidson BR (2010) Miniport versus standard ports for laparoscopic cholecystectomy. *Cochrane Database Syst Rev* CD006804
  25. Ficarra V, Novara G, Artibani W, Cestari A, Galfano A, Graefen M, Guazzoni G, Guillonneau B, Menon M, Montorsi F, Patel V, Rassweiler J, Van PH (2009) Retropubic, laparoscopic, and robot-assisted radical prostatectomy: a systematic review and cumulative analysis of comparative studies. *Eur Urol* 55:1037–1063