

Partial Molar Pregnancy with Live Fetus Diagnosed on Second Trimester: A Case Report

Angela Santos^{1*}, Vera Trocado², Ana Paula Gama³, Paula Pinheiro⁴, Rosete Nogueira⁵

¹Interna de Formação Específica de Ginecologia-Obstetrícia, Serviço de Ginecologia- Obstetrícia, Unidade Local de Saúde do Alto Minho, Viana do Castelo, Portugal

²Interna de Formação Específica de Ginecologia-Obstetrícia, Serviço de Ginecologia- Obstetrícia, Unidade Local de Saúde do Alto Minho, Viana do Castelo, Portugal e Assistente Convidada da Universidade do Minho, Surgical Sciences Research Domain, Life and Health Sciences Research Domain ICVS/3B's – PT Government Associate Laboratory, Braga, Portugal

³Assistente Hospitalar de Ginecologia-Obstetrícia, Serviço de Ginecologia-Obstetrícia, Unidade Local de Saúde do Alto Minho, Viana do Castelo, Portugal

⁴Assistente Graduada de Ginecologia-Obstetrícia, Serviço de Ginecologia-Obstetrícia da Unidade Local de Saúde do Alto Minho, Viana do Castelo, Portugal

⁵Consultora em Anatomia Patológica, Diretora do Laboratório de Anatomia Patológica/Embriofetopatologia do CGC Genetics, Porto, Portugal e Professora Auxiliar da Universidade do Minho, Surgical Sciences Research Domain, Life and Health Sciences Research Domain ICVS/3B's - PT Government Associate Laboratory, Braga, Portugal

***Corresponding author:** Ângela Santos, Avenida Santo André, Edifício Mira Rio, nº 241, Apartamento 1001, 4755-281, Barcelinhos-Barcelos, Portugal, Tel: 00351914502783; E-mail: angelacmsantos@gmail.com

Abstract

Hydatidiform mole is part of a group of diseases classified as gestational trophoblastic disease, which results from an aberrant fertilization. They are associated with an increase risk for the development of neoplasm, specifically choriocarcinoma, a malignant tumor that has a potential to locally invade the uterus and metastasize. Traditionally, moles have been categorized into complete or partial hydatidiform moles. Partial moles are most commonly triploid and are associated with the presence of a malformed fetus. Often partial moles are misdiagnosed as an incomplete or missed abortion of the first trimester. A case of a partial molar pregnancy with live fetus diagnosed on second trimester is reported. Hyperemesis gravidarum and hyperthyroidism were the clinical presentations. Human chorionic gonadotropin level was 1 891 264 mIU/mL. Fetal karyotype was 69, XXX. Surgical uterine evacuation was performed and the patient is in follow up. Partial molar pregnancy with a live fetus is a rare condition that presents a challenging diagnosis, particularly when it is detected during the second trimester of pregnancy.

Received date: April 12, 2017

Accepted date: July 10, 2017

Published date: July 14, 2017

Citation: Angela S., et al. Partial Molar Pregnancy with Live Fetus Diagnosed on Second Trimester: A Case Report. (2017) J Gynecol Neonatal Biol 3(2): 1- 4.

DOI: 10.15436/2380-5595.17.1475



Keywords: Partial molar pregnancy; Second trimester; Live fetus; Triploid; Fetal karyotype

Introduction

Molar pregnancy is part of a group of diseases classified as Gestational Trophoblastic Disease (GTD), which originate in the placenta and may locally invade the uterus and metastasize^[1]. Hydatidiform Moles (HM) are traditionally categorized as complete or partial, which differ by gross morphology, histopathology, karyotype, risk of malignancy and fetal characteristics phenotype features^[2,3]. Partial Moles (PM) are most commonly triploid, resulting from fertilization of an ap-

parently normal ovum by two sperm or a diploid sperm and may be 69XXX, 69 XXY or 69 XYY^[2,3]. PM is the only type of GTD associated with the presence of a fetus and cardiac activity may be detected^[4]. As serum Human Chorionic Gonadotropin (hCG) levels are generally lower than in complete mola, consequences of hCG stimulation, - uterine enlargement, hyperemesis gravidarum, theca lutein cysts, hyperthyroidism and early onset of preeclampsia, are less likely to occur^[5]. The availability of both



ultrasonography and sensitive measurement of serum hCG has led to earlier diagnosis of HM, usually on first trimester^[6]. The PM gross and microscopic features are similar to the Complete Mole (CM) but the features are less conspicuous in PM. We present a case of a partial molar pregnancy with an apparently normal fetus and it's challenging diagnosis during the second trimester.

Material and Methods

The authors present a case report of a partial molar pregnancy with an apparently normal fetus and it's challenging diagnosis during the second trimester. Hyperemesis and hyperthyroidism were the first presentation. A review of literature is also presented.

Results

A 28 year-old woman, gravida 1 para 0, blood type O positive, no relevant medical history, was admitted in our institution at 7 weeks and 5 days of gestational age with hyperemesis gravidarum. Obstetrical ultrasound revealed a singleton viable pregnancy. Clinical hyperthyroidism was diagnosed (Thyroid-Stimulating Hormone – TSH - 0,01 mU/L; free thyroxin - T4- 1,61 mU/L) and Propylthiouracil was initiated. She had no other abnormal laboratory or imaging studies and was discharged 20 days after. Readmitted at 11 weeks with persistent vomiting, severe dehydration and weight loss of 5 kg. Obstetrical ultrasound confirmed a viable pregnancy. She presented TSH -0,01 mU/L and free T4 - 1,58 mU/L. Remaining laboratory tests were normal. Discharged after gradual improvement with rehydration and intravenous antiemetic therapy. First trimester screening for chromosomal abnormalities (ultrasound and biochemistry), was negative (1:2386). At 15 weeks of gestational age our patient was readmitted with persistent vomiting, nausea and weakness. Pelvic examination and laboratory evaluation, including complete blood count, renal panel, serum electrolytes, liver function and abdominal ultrasound, were normal. Free T4 was normal (0,81 mU/L) and TSH was 0,07 mU/L.

Obstetrical ultrasound revealed a live fetus, biometry compatible with fifteenth week of gestational age, no structural abnormalities and normal amniotic fluid index. An enlarged placenta with multiple diffuse cystic spaces (“Swiss cheese pattern”) (Figure 1, 2) and bilateral multiloculated theca lutein cysts (Figure 3, 4) were observed for the first time. Serum free β – hCG: 1 891 264 mIU/mL. The patient underwent amniocentesis that revealed a triploid karyotype: 69, XXX. The couple required some time to think about termination of pregnancy. During that time fetal death occurred. Surgical uterine evacuation was performed at 20 weeks of gestational age. Fetal autopsy discloses hydrops and intrauterine growth restriction, micrognathia and minor limb anomalies without other major external relevant features, severe pulmonary hypoplasia, perimembranous ventricular septal defect and intestinal malrotation are also documented. The placenta had a voluminous size and is composed of normal appearing villous tissue intermixed with larger, distended villi or vesicles with maximum diameter of 2.5 cm. umbilical cord with 25 cm length and 3 vessels, and membranes are also present. Fetal and placenta's histology was performed and documented severe erythroblastosis and hydrops's. Analysis of the placenta

confirm an admixture of two populations of villi (normal and hydropic); enlarged chorionic villi with cavitation (vesicles); irregular villi with scalloped borders and trophoblastic pseudo-inclusion and focal, mild trophoblastic hyperplasia compatible with a partial molar pregnancy (Figure 5). Serum hCG one week after evacuation: 28 266 mIU/mL, one month later: 520 mIU/mL. The patient is in follow up. Theca lutein cysts regressed three months after uterine evacuation and hCG levels have been negative for six months.

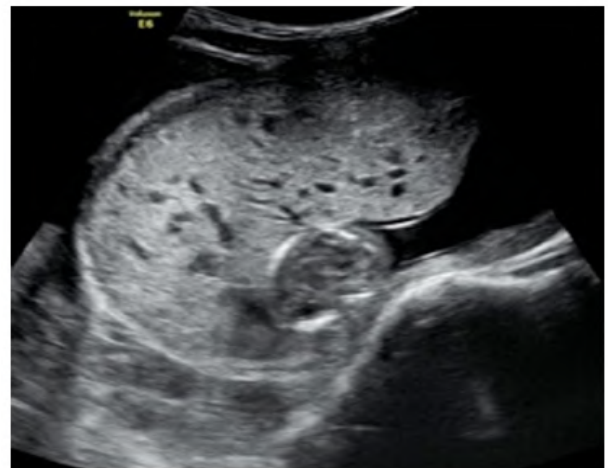

Figure 1: Obstetrical ultrasound at 15 weeks of gestational age revealing a placenta with multiple diffuse cystic spaces.

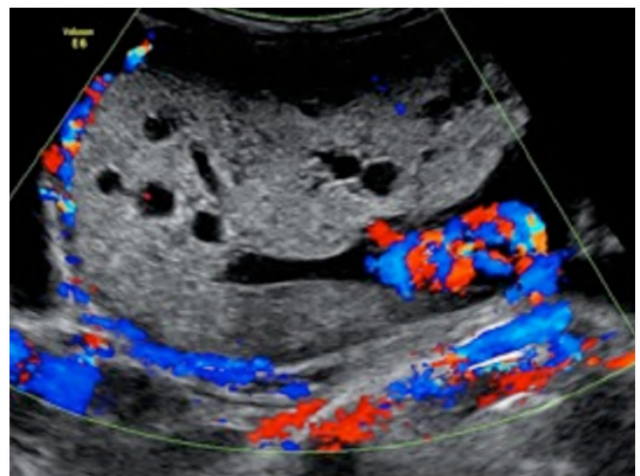
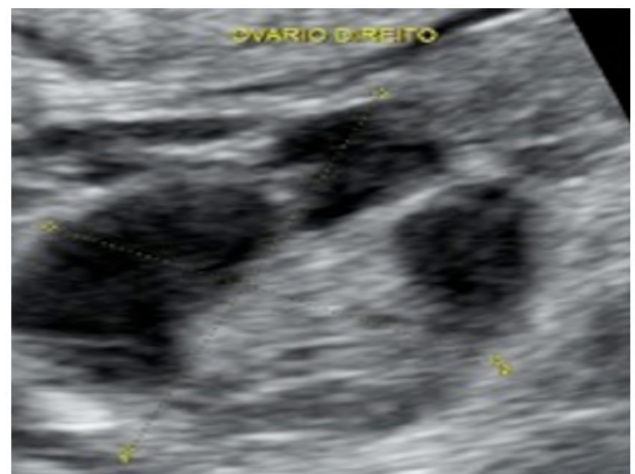

Figure 2: Placenta with a “swiss cheese pattern”.



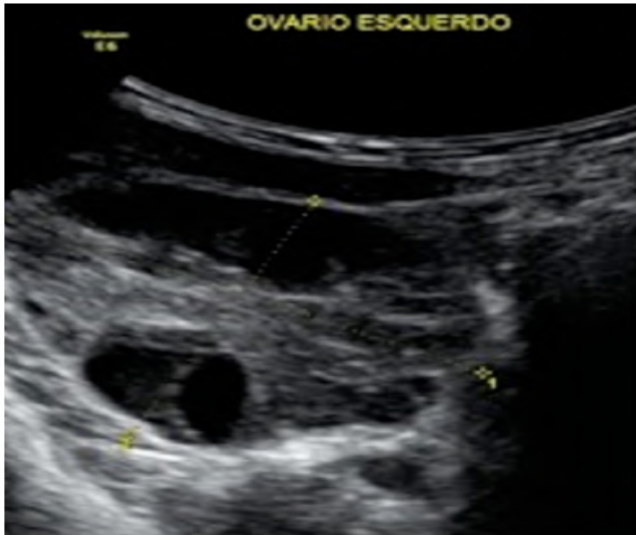


Figure 3 and 4: Right and left ovary with multiloculated cysts.

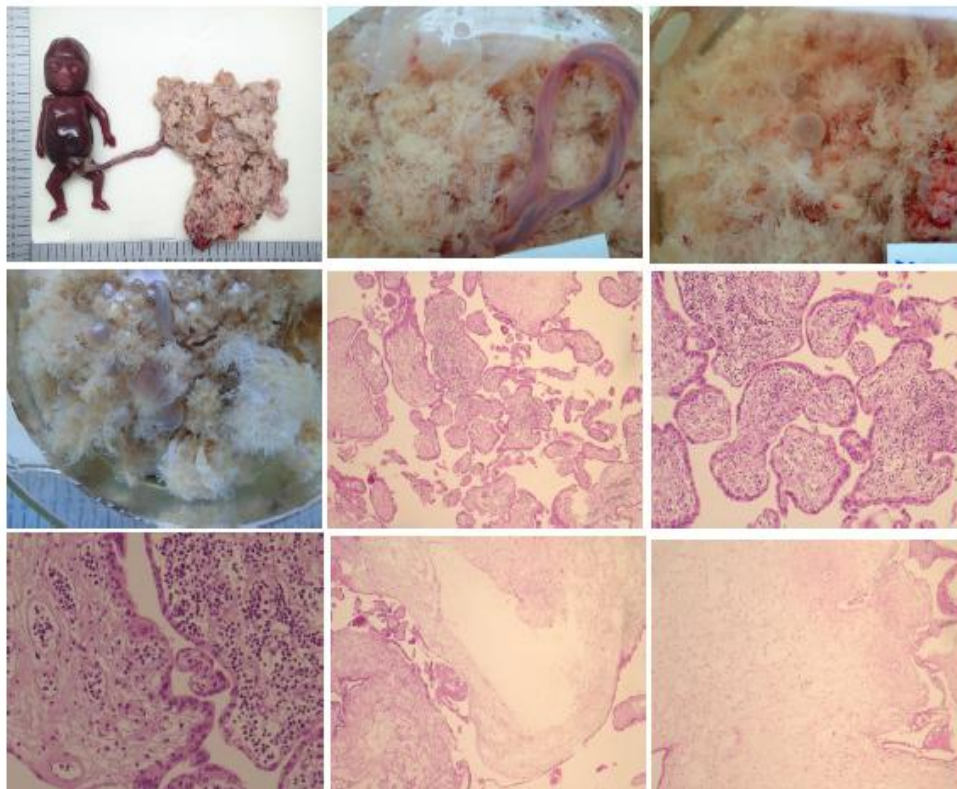


Figure 5. Gross features: fetal and placental hydropsis, a; Partial hydatidiform mole photographed under water with bulbous swelling of villi, b,c,d. Microscopic features H&E: admixture of two populations of villi (normal and hydropic), e, (x20); erythroblastosis, f,g (x20 and x40); molar villi showing irregular proliferation of trophoblast with lacy extensions(x40).

Conclusion

Partial Mole (PM) usually derives from dispermic fertilization of a haploid normal oocyte and produces a triplet set of chromosomes that leads to the presence of an embryo/fetus with multiple malformations that commonly demises in utero in the first trimester^[3]. PM with coexisting live fetus is a rare complication with the incidence of 0.005 - 0.01 % of all pregnancies^[8-10]. This case is particularly interesting as the clinical presentation of PM was a hyperemesis gravidarum associated with clinical hyperthyroidism since the seventh week of gestational age. A review of 81 women with PM, reported in 1985 by Berkowitz et al, found that hyperemesis gravidarum and hyperthyroidism occurred in only 1%^[4], due to hCG levels typically far lower than in complete mole. First trimester screening for chromosomal abnormalities was negative, presenting a normal hCG value (739 mIU/mL) and there were no abnormal ultrasound findings until the fifteenth week of gestational age. Then we found an enlarged placenta with diffuse cystic spaces and a normal appearing fetus. Theca lutein cysts occur in 1% of PM^[4]. Our patient had bilateral multiloculated ovarian cysts with 46 and 60 mm (right and left ovary, respectively). hCG level > 100 000 mIU/mL occurs in 6 % of PM^[4]. Our patient had 1 891

264 mIU/mL. In that moment the differential diagnosis included a dizygotic twin pregnancy with one complete or partial HM and one normal twin, a singleton normal fetus with partial mole after focal or diffuse degeneration of the placenta, a placental tumor or a placental mesenchymal dysplasia^[7,8,11-13]. Fetal karyotype was determinant for the suspicious diagnosis of PM as it revealed a triploid fetus. Placenta's histopathology confirmed PM. Diagnosis and management of molar pregnancies with an apparently normal fetus, especially in the second trimester, remains challenging. Serum hCG levels can be a helpful marker as well as the determination of the fetal karyotype. When a triploid fetus is present, termination of pregnancy should be promptly considered and the patient must be kept in follow up until six consecutive mensal negative hCG levels.

Conflicts of Interest: The authors declare that there are no conflicts of interest.

Funding: No subsidies or grants contributed to this work.

REFERENCES

1. Berkowitz, R.S., Goldstein, D.P. Current advances in the management of gestational trophoblastic disease. *Gynecol Oncol* 2013; 128(1): 3-5.
[Pubmed](#) | [Crossref](#) | [Others](#)
2. Vassilakos, P., Riotton, G., Kajii, T. Hydatidiform mole: two entities. A morphologic and cytogenetic study with some clinical consideration. (1977) *Am J Obstet Gynecol* 127(2): 167-170.
[Pubmed](#) | [Crossref](#) | [Others](#)
3. Szulman, A.E., Surti, U. The clinicopathologic profile of the partial hydatidiform mole. (1982) *Obstet Gynecol* 59(5): 597-602.
[Pubmed](#) | [Crossref](#) | [Others](#)
4. Berkowitz, R.S., Goldstein, D.P., Bernstein, M.R. Natural history of partial molar pregnancy. (1985) *Obstet Gynecol* 66(5): 677-681.
[Pubmed](#) | [Crossref](#) | [Others](#)
5. Berkowitz, R.S., Goldstein, D.P. Clinical practice. Molar pregnancy. (2009) *N Engl J Med* 360(16): 1639-1645.
[Pubmed](#) | [Crossref](#) | [Others](#)
6. Sebire NJ. The diagnosis of gestational trophoblastic disease in early pregnancy: implications for screening, counseling and management. *Ultrasound Obstet Gynecol* 2005; 25(5): 421-424.
[Pubmed](#) | [Crossref](#) | [Others](#)
7. Juárez, A., Diminguez, L., Padilla, M. Mola Hidatidiforme parcial com feto vivo del segundo trimestre. (2010) *Rev Chil Obstet Ginecol* 75(2): 137-139.
[Pubmed](#) | [Crossref](#) | [Others](#)
8. Rahamni, M., Parviz, S. A case report of partial molar pregnancy associated with a normal appearing dizygotic fetus. (2016) *Asian Pac J Reprod* 5(2): 171-173.
[Pubmed](#) | [Crossref](#) | [Others](#)
9. Pérez de Castilla, J., Carmona de Uzategui, M., Moreno, I. Estudio anatomopatológico de un caso de mola parcial. (2006) *Rev Obstet Ginecol Venez* 66: 1-4.
[Pubmed](#) | [Crossref](#) | [Others](#)
10. Suzuki, M., Matsunobu, A., Vakita, K., et al. Hydatidiform mole with surviving co-existent fetus. (1980) *Obst Gynecol* 56(3): 384-388.
[Pubmed](#) | [Crossref](#) | [Others](#)
11. Wang, Y., Qian, H., Wang, J. Medical termination of a partial hydatidiform mole and coexisting fetus during the second trimester: A case report. (2015) *Oncol Lett* 10(6): 3625-3628.
[Pubmed](#) | [Crossref](#) | [Others](#)
12. Hsieh, C.C., Hsieh, T.T., Hsieh, C., et al. Delivery of a severely anaemic fetus after partial molar pregnancy: clinical and ultrasonography findings. (1999) *Human Reproduction* 14(4): 1122-1126.
[Pubmed](#) | [Crossref](#) | [Others](#)
13. Godinho, A.B., Martins, D., Araújo, C., et al. Gravidez gemelar com uma mola hidatiforme completa e um co-gêmeo viável. (2014) *Acta Med Port* 27(1): 135-137.
[Pubmed](#) | [Crossref](#) | [Others](#)