



Helicobacter pylori colonization of the adenotonsillar tissue: Fact or fiction?

Sérgio Vilarinho^{a,1}, Nuno M. Guimarães^{b,c,1}, Rui M. Ferreira^{b,d,1}, Bárbara Gomes^e, Xiaogang Wen^b, Maria J. Vieira^c, Fátima Carneiro^{b,d,e}, Tiago Godinho^a, Ceu Figueiredo^{b,d,*}

^aServiço de Otorrinolaringologia, Hospital de São Marcos, Braga, Portugal

^bInstitute of Molecular Pathology and Immunology of the University of Porto (IPATIMUP), Porto, Portugal

^cInstitute for Biotechnology and Bioengineering (IBB), Centre of Biological Engineering, Universidade do Minho, Braga, Portugal

^dFaculty of Medicine of the University of Porto, Porto, Portugal

^eDepartment of Pathology, Hospital de S. João, Porto, Portugal

ARTICLE INFO

Article history:

Received 23 March 2010

Received in revised form 13 April 2010

Accepted 14 April 2010

Available online 8 May 2010

Keywords:

Helicobacter pylori

Adenotonsillar tissue

PCR

Rapid urease test

Immunohistochemistry

PNA-FISH

ABSTRACT

Objective: The transmission of the gastric pathogen *Helicobacter pylori* involves the oral route. Molecular techniques have allowed the detection of *H. pylori* DNA in samples of the oral cavity, although culture of *H. pylori* from these type of samples has been sporadic. Studies have tried to demonstrate the presence of *H. pylori* in adenotonsillar tissue, with contradictory results. Our aim was to clarify whether the adenotonsillar tissue may constitute an extra gastric reservoir for *H. pylori*.

Methods: Sixty-two children proposed for adenoidectomy or tonsillectomy were enrolled. A total of 101 surgical specimens, 55 adenoid and 46 tonsils, were obtained. Patients were characterized for the presence of anti-*H. pylori* antibodies by serology. On each surgical sample rapid urease test, immunohistochemistry, fluorescence *in situ* hybridization (FISH) with a peptide nucleic acid probe for *H. pylori*, and polymerase chain reaction–DNA hybridization assay (PCR–DEIA) directed to the *vacA* gene of *H. pylori* were performed.

Results: Thirty-nine percent of the individuals had anti-*H. pylori* antibodies. Rapid urease test was positive in samples of three patients, all with positive serology. Immunohistochemistry was positive in samples of two patients, all with negative serology. All rapid urease test or immunohistochemistry positive cases were negative by FISH. All samples tested were negative when PCR–DEIA for *H. pylori* detection was used directly in adenotonsillar specimens.

Conclusions: The adenotonsillar tissue does not constitute an extra gastric reservoir for *H. pylori* infection, at least a permanent one, in this population of children. Moreover, techniques currently used for detecting gastric *H. pylori* colonization are not adequate to evaluate infection of the adenotonsillar tissues.

© 2010 Elsevier Ireland Ltd. All rights reserved.

1. Introduction

Helicobacter pylori is considered the most frequent chronic infection of humans, with more than half of the world's population being infected [1]. *H. pylori* is a microaerophilic, gram negative bacterium that persistently colonizes the human gastric mucosa. The infection is usually acquired early in childhood and can persist for the lifetime of the host if not treated [1]. *H. pylori* infection occurs worldwide, but its prevalence is significantly different between countries [2]. Studies of risk factors for *H. pylori* infection

have associated the prevalence of infection with the socioeconomic indicators, with higher prevalence in developing regions and lower prevalence in developed regions [2].

The transmission of *H. pylori* is still poorly understood, but the faecal–oral and the oral–oral are the most consensual routes of transmission [1,2]. The presence of *H. pylori* in the oral cavity has been detected in samples from supragingival plaque, dental plaque and saliva by polymerase chain reaction [2–4], but culture of the bacteria from this type of samples has been sporadic. More recently, it has also been suggested that adenotonsillar tissues may be a reservoir for *H. pylori*, and several studies evaluated the presence of *H. pylori* in adenoid and tonsil specimens [5–7]. However, results have been contradictory and, most importantly, techniques used to detect *H. pylori* in these tissues were not appropriate. Therefore, our aim was to clarify whether the adenotonsillar tissue may constitute an extra gastric reservoir for *H. pylori*. We have studied 62 children proposed for

* Corresponding author at: Institute of Molecular Pathology and Immunology of the University of Porto (IPATIMUP), Rua Dr. Roberto Frias S/N, 4200-465 Porto, Portugal. Tel.: +351 225570779; fax: +351 225570799.

E-mail address: cfigueiredo@ipatimup.pt (C. Figueiredo).

¹ Equal contribution.

adenoidectomy and/or tonsillectomy, and a total of 101 samples (55 adenoid and 46 tonsils) were characterized for the presence of *H. pylori* using different techniques.

2. Materials and methods

2.1. Patients and surgical procedures

Patients were consecutively selected from the surgical waitlist for adenoidectomy and/or tonsillectomy, with or without treatment of middle ear disease, and that had not been treated with antibiotics nor with proton pump inhibitors on the 4 weeks prior to surgery. Sixty-two patients (mean age = 7.9 ± 5.5 years and male/female ratio of 1:1.2) fulfilled these criteria and were recruited for this study. Thirty-nine patients (62.9%) underwent adenoidectomy, 16 patients (25.8%) underwent adenotonsillectomy and seven patients (11.3%) underwent tonsillectomy at the Hospital São Marcos, Braga, Portugal. Routine surgical indications for adenotonsillectomy were followed. All patients were operated under general anaesthesia. Blockage of gastro-pharyngeal reflux was obtained with gauze placed on the hypopharynx after oro-tracheal intubation and before trendelenburg positioning. Protocols followed in the study were in accordance with the institutional ethical standards. Informed consent was obtained from the patients' parents. Samples were delinked and unidentified from their donors.

2.2. Serology

Serum samples were used for detection of IgG antibodies against *H. pylori*, using the Pyloriset EIA-G III Kit (Orion Diagnostics, Espoo, Finland). The assay was performed following the manufacturer's instructions.

2.3. Rapid urease test

A 1 mm³ sample from each surgical specimen was immersed in urea broth medium containing phenol red (Fluka, Buchs, Switzerland) and incubated for 24 h at 37 °C. At the end of that time period, colour changes in medium were registered.

2.4. Histology and immunohistochemistry

Surgical specimens were formalin fixed, paraffin embedded, and sections of 3 µm were cut. Slides were deparaffinised in xylol and hydrated with grade ethanol concentrations, and stained with haematoxylin and eosin, modified Giemsa and with a rabbit anti-human polyclonal antibody against *H. pylori* (Cell Marque, CA, USA). Briefly, antigen retrieval was performed by microwave pre-treatment in 10 mmol/L citrate buffer (pH 6.0) for 15 min. Endogenous peroxidase activity was blocked with hydrogen peroxide block solution (Labvision, UK) for 10 min. After washing in phosphate buffered saline (PBS), sections were incubated for 30 min with primary antibody (1:500). Staining was achieved using Dako RealTM EmvisionTM/HRP rabbit/mouse polymer, for 30 min at room temperature. Binding was detected using diaminobenzidine (DAB), which upon oxidation forms a stable brown end-product. Nuclei were slightly counterstained with Mayer's haematoxylin. Gastric biopsies positive for *H. pylori* infection were used as positive controls. Slides were visualized by two experienced pathologists that were blind to the patients' clinical data.

2.5. PNA-FISH

H. pylori was detected in the adenotonsillar samples using the Hpy769 probe, a peptide nucleic acid probe (PNA) that is highly

specific and sensitive for the detection of *H. pylori* [8]. The surgical specimens were deparaffinised and rehydrated in xylol and ethanol. Samples were immersed twice in xylol for 15 min, and in decreasing concentrations of ethanol for 5 min, and were finally washed with distilled water for 10 min. Samples were allowed to air dry and the fluorescence *in situ* hybridization (FISH) procedure was performed as described in Guimarães et al. [8].

2.6. DNA isolation

DNA was isolated of 8 mm³ fragments from all surgical specimens using the DNA Invisorb Spin Tissue Mini Kit (Invitex, Berlin, Germany). The extraction was performed following the manufacturer's instructions. In a subset of cases, the whole surgical specimen was fully homogenized in Tris-EDTA buffer (10 mM Tris pH 7.5, 1 mM EDTA) using an ultraturax homogenizer and DNA was isolated.

2.7. PCR and DEIA

Detection of the *vacA* gene of *H. pylori* was performed using primers VA1F and VA1XR, described previously [9]. PCR reaction mixtures were performed in a volume of 25 µL, 1× PCR Buffer, 2.5 mmol/L of MgCl₂, 0.25 mmol/L dNTPs, 0.25 U AmpliTaq Gold, and 25 pmol of each primer. PCR was performed with 9 min pre-denaturation at 95 °C, followed by 40 cycles of 30 s at 95 °C, 45 s at 50 °C, and 45 s at 72 °C. Final extension was performed for 10 min at 72 °C. Amplimers carrying a biotin moiety at the 5' terminus of the reverse primer were detected in a microtiter well-based DNA hybridization assay (DEIA) using a specific general probe for the *vacA* gene [10,11]. DNA isolated from *H. pylori* Tx30a (ATCC 51932, American Type Tissue Culture) and 26695 (ATCC 700392) strains was used as reference.

2.8. Statistical analyses

Age distribution between *H. pylori* seropositives and seronegatives was analysed by the Student's *t*-test. Association between gender and *H. pylori* serology was assessed by the Pearson Chi-Square test. Logistic regression models were computed with Statview for Windows software (version 5.0; SAS Institute Inc., Cary, NC). Differences in data values were considered significant at *p* values lower than 0.05.

3. Results

The study population was constituted by 62 children living in the North of Portugal, which were indicated to surgery due to adenotonsillar hypertrophy (47 cases), infection (5 cases) or both (10 cases). Sixty-two blood samples and 101 surgical samples (55 adenoids, 23 left tonsils and 23 right tonsils) were obtained.

The presence of anti-*H. pylori* antibodies in serum was detected in 24 (39%) cases. Infected patients were older than uninfected patients (*p* = 0.013) and were more frequently females (*p* = 0.044) (Table 1). In a logistic regression analysis, including both gender and age in the model, only age remained associated with *H. pylori* seropositivity (*p* = 0.039).

To evaluate the presence of *H. pylori* in the adenotonsillar tissues, we have used the rapid urease test, immunohistochemistry with a polyclonal anti-*H. pylori* antibody, FISH with a specific *H. pylori* PNA probe, and PCR-DEIA for *H. pylori vacA* gene (Table 2).

The rapid urease test was positive in two (3.6%) adenoid and in two (4.3%) tonsil specimens from three patients. All urease test positive samples were from patients infected with *H. pylori* as evaluated by serology.

Table 1
Characteristics and *H. pylori* serology in the studied individuals.

	Serology		p value ^a
	Negative (n=38)	Positive (n=24)	
Age (average ± SE)	6.5 ± 0.6	10.1 ± 1.5	0.013
Gender			
Female	17	17	0.044
Male	21	7	

^a Univariate analysis; SE: standard error.

Table 2
H. pylori detection in adenotonsillar tissues by different methods.

Method	Adenoids (n=55)	Tonsils (n=46)
Rapid urease test	2 (3.6%)	2 (4.3%)
Immunohistochemistry	0 (0%)	3 (6.5%)
PNA-FISH	0 (0%)	0 (0%)
PCR-DEIA	0 (0%)	0 (0%)

PNA-FISH: peptide nucleic acid-fluorescence *in situ* hybridization; PCR-DEIA: polymerase chain reaction-DNA hybridization assay.

Immunohistochemistry was positive in three tonsil specimens from two patients (Fig. 1), and these patients were *H. pylori* serology negative. FISH using a specific PNA probe for *H. pylori* was negative in paraffin cuts consecutive to those used for immuno-

histochemistry (Fig. 2). PNA-FISH was negative in all studied specimens.

The presence of *H. pylori* in the adenotonsillar samples was also assessed by PCR, directed to the *vacA* gene, which is present in all strains of *H. pylori*. In order to improve the sensitivity of the PCR, amplimers were hybridized with a *vacA* specific probe in DEIA assays. All samples were negative for the presence of *H. pylori*. To exclude sampling bias, in a subset of cases corresponding to those that were ELISA positive, DNA isolation was performed after fully homogenizing the whole surgical specimen. All cases were negative for *H. pylori*.

4. Discussion

Data concerning the presence of *H. pylori* in adenoids and/or tonsils are inconsistent. In this study we have initially characterized all patients for the presence of serum anti-*H. pylori* IgG antibodies. In agreement with previously published data on the prevalence of *H. pylori* infection in the Portuguese population in paediatric age, 39% of the patients were *H. pylori* positive [12]. The presence of the infection was associated with older patients and, in keeping with previous studies, gender did not constitute a risk factor for *H. pylori* infection [13].

To clarify whether *H. pylori* is present in the adenotonsillar tissues of these children, we have used a variety of approaches

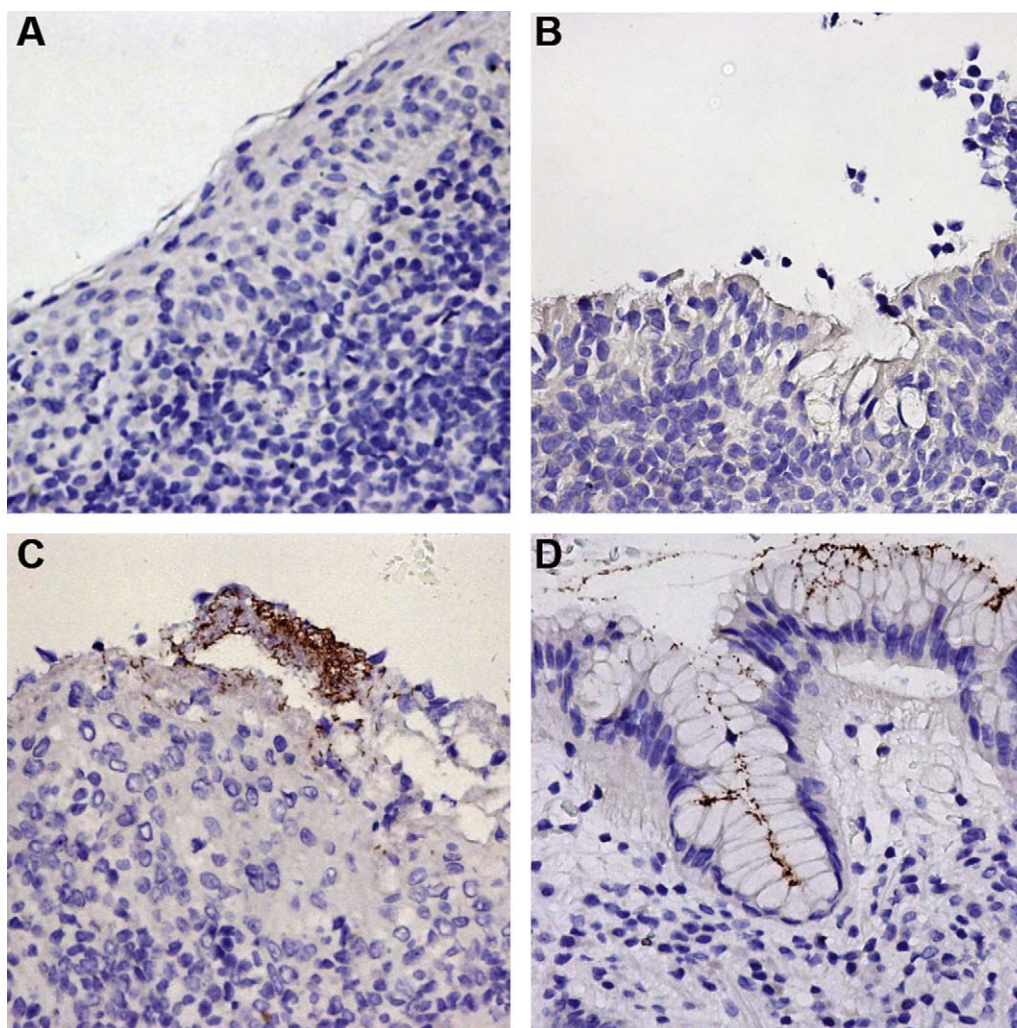


Fig. 1. Immunohistochemistry using a polyclonal anti-*H. pylori* antibody in adenoid and tonsil surgical specimens. (A) and (B) Negative specimens; (C) tonsil specimen showing *H. pylori*-like microorganisms; (D) *H. pylori*-infected gastric mucosa used as positive control.

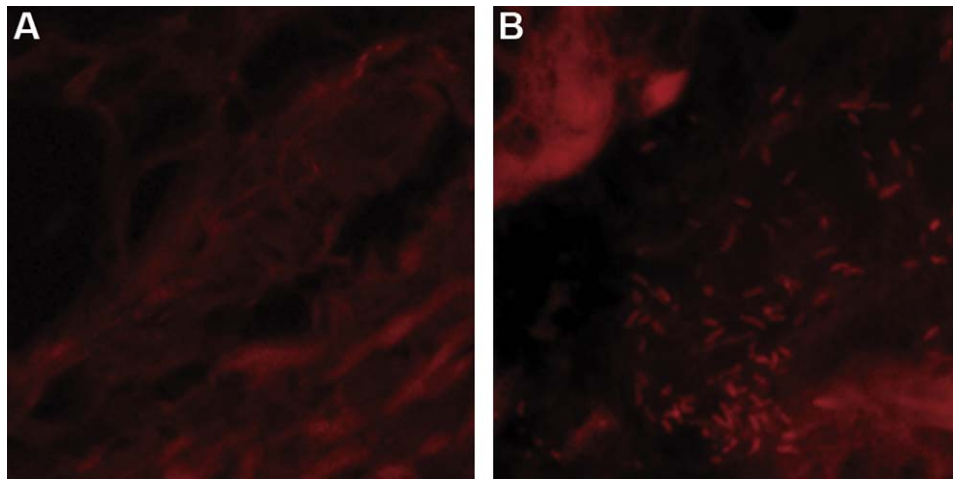


Fig. 2. Peptide nucleic acid–fluorescence *in situ* hybridization (PNA–FISH) for *H. pylori* detection in adenoid and tonsil surgical specimens: (A) negative tonsil specimen; (B) *H. pylori*-infected gastric mucosa used as positive control.

directly aimed at the tissue samples. Therefore, each adenoidal and tonsillar specimen was submitted to rapid urease test, immunohistochemistry, PNA–FISH and PCR–DEIA. We detected urease-positive microorganisms in four tissue specimens of three patients with positive *H. pylori* serology. However, we also demonstrated by immunohistochemistry, PNA–FISH and PCR–DEIA that these urease-producing microorganisms were not *H. pylori*. Though immunohistochemistry was positive in three tonsil specimens from two patients, these specimens were *H. pylori*-negative by PNA–FISH and PCR–DEIA, and the patients did not present antibodies anti-*H. pylori*.

All adenotonsillar specimens included in this study were negative when PNA–FISH or PCR–DEIA were used. The PNA–FISH method has been previously tested in different types of samples and with different microorganisms, and has shown a high specificity for *H. pylori* [8]. PCR is recognized as having high specificity if the target gene and the primers are carefully chosen. In this study, we have used as amplification target *H. pylori vacA* gene that, besides having no homology to other bacterial species, is present in all *H. pylori* strains. The primers used are well established and their high sensitivity and specificity has been previously demonstrated [10,11]. PCR sensitivity was increased by hybridization of amplified products with a specific *vacA* probe [11].

Considering that PNA–FISH and PCR–DEIA are the most specific and sensitive methods and that all tissue samples analyzed were negative, results obtained by rapid urease test and immunohistochemistry are false positives. Several studies have reported the presence of *H. pylori* in adenoid and/or tonsillar tissues based on the solely use of rapid urease test [6,7]. However, we and others showed that, in cases positive for the rapid urease test, the use of additional detection methods reveals that those are likely false-positive results [14,15]. One very important aspect concerns the specificity of the rapid urease test and of immunohistochemistry. These are related with the probability of the presence in the sample of microorganisms, other than *H. pylori*, that could origin cross reactivity leading to false-positive results. So, although these techniques have a high specificity when used in gastric samples, the specificity may be lower in samples from polymicrobial environments such as the adenotonsillar tissues [14]. The rapid urease test is not in fact a specific test for *H. pylori*, but for urease-producing microorganisms. Therefore, the positive results that we have obtained probably reflect the presence in adenotonsillar tissues of other urease-producing bacteria. Likewise, and although immunohistochemistry allows higher reproducibility of *H. pylori* detection in gastric samples when compared with conventional

histological techniques [16], in polymicrobial extra gastric samples antibodies can recognize bacterial epitopes other than *H. pylori*, leading to false-positive results.

The negative results we have obtained by PNA–FISH and PCR–DEIA are also in accordance with previously published data using PCR and/or culture [14,15,17–20]. The use of PCR for detection of *H. pylori* in adenotonsillar tissues has sporadically given positive results [21]. However, primer choice needs to be viewed with caution, since certain primer sets used for detection of *H. pylori* produce a very high rate of false-positive results [22].

The main limitation of this study is related with the fact that the gastric infection status of the studied population was only evaluated by IgG serology, which is not specific for active gastric *H. pylori* infection. Therefore, we cannot exclude the possibility that the adenoids and tonsils are infected only in cases of active or recurrent disease. Furthermore, and because *H. pylori* infection is less common in the paediatric population than in adults, the lack of adenotonsillar *H. pylori* infection in children does not exclude this possibility in the adult population.

5. Conclusion

The adenotonsillar tissue does not constitute an extra gastric reservoir for *H. pylori* infection, at least a permanent one, in this population of children. Furthermore, techniques currently used for detecting gastric *H. pylori* colonization are not adequate to evaluate infection of the adenotonsillar tissues.

Acknowledgements

Part of this work was presented at the 22nd Annual Meeting of the European *Helicobacter* Study Group, Porto, Portugal, September 17–19, 2009. This research was supported by the Portuguese Fundação para a Ciência e a Tecnologia grants SFRH/BD/24579/2005 and SFRH/BD/45841/2008. The authors wish to thank Dr. João Anjos, Dr. António Marques, Dr. Mário Carvalho, Dr. Anabela Correia, and the staff of the Serviço de Otorrinolaringologia do Hospital de São Marcos, Braga, for technical assistance and support.

References

- [1] N.F. Azevedo, N. Guimaraes, C. Figueiredo, C.W. Keevil, M.J. Vieira, A new model for the transmission of *Helicobacter pylori*: role of environmental reservoirs as gene pools to increase strain diversity, *Crit. Rev. Microbiol.* 33 (2007) 157–169.
- [2] N.F. Azevedo, J. Huntington, K.J. Goodman, The epidemiology of *Helicobacter pylori* and public health implications, *Helicobacter* 14 (Suppl. 1) (2009) 1–7.

- [3] M. Czesnikiewicz-Guzik, W. Bielanski, T.J. Guzik, B. Loster, S.J. Konturek, *Helicobacter pylori* in the oral cavity and its implications for gastric infection, periodontal health, immunology and dyspepsia, *J. Physiol. Pharmacol.* 56 (Suppl. 6) (2005) 77–89.
- [4] Y. Liu, H. Yue, A. Li, et al., An epidemiologic study on the correlation between oral *Helicobacter pylori* and gastric *H. pylori*, *Curr. Microbiol.* 58 (2009) 449–453.
- [5] B.V. Agirdir, S. Bozova, A.T. Derin, M. Turhan, Chronic otitis media with effusion and *Helicobacter pylori*, *Int. J. Pediatr. Otorhinolaryngol.* 70 (2006) 829–834.
- [6] B. Khademi, N. Niknejad, B. Gandomi, F. Yeganeh, Comparison of *Helicobacter pylori* colonization on the tonsillar surface versus tonsillar core tissue as determined by the CLO test, *Ear Nose Throat J.* 86 (2007) 498–501.
- [7] S. Unver, U. Kubilay, O.S. Sezen, T. Coskuner, Investigation of *Helicobacter pylori* colonization in adenotonsillectomy specimens by means of the CLO test, *Laryngoscope* 111 (2001) 2183–2186.
- [8] N. Guimaraes, N.F. Azevedo, C. Figueiredo, C.W. Keevil, M.J. Vieira, Development and application of a novel peptide nucleic acid probe for the specific detection of *Helicobacter pylori* in gastric biopsies, *J. Clin. Microbiol.* 45 (2007) 3089–3094.
- [9] L.J. van Doorn, C. Figueiredo, R. Rossau, et al., Typing of *Helicobacter pylori* vacA gene and detection of cagA gene by PCR and reverse hybridization, *J. Clin. Microbiol.* 36 (1998) 1271–1276.
- [10] L.J. van Doorn, C. Figueiredo, R. Sanna, et al., Expanding allelic diversity of *Helicobacter pylori* vacA, *J. Clin. Microbiol.* 36 (1998) 2597–2603.
- [11] L.J. van Doorn, Y. Henskens, N. Nouhan, et al., The efficacy of laboratory diagnosis of *Helicobacter pylori* infections in gastric biopsy specimens is related to bacterial density and vacA, cagA, and iceA genotypes, *J. Clin. Microbiol.* 38 (2000) 13–17.
- [12] M.G. Quina, *Helicobacter pylori*: the Portuguese scene. Grupo de Estudo Portugues do *Helicobacter pylori* (GEPHP), *Eur. J. Cancer Prev.* 3 (Suppl. 2) (1994) 65–67.
- [13] M.N. Rodrigues, D.M.M. Queiroz, J.G.B. Filho, L.K. Pontes, R.T. Rodrigues, L.L.B.C. Braga, Prevalence of *Helicobacter pylori* infection in children from an urban community in north-east Brazil and risk factors for infection, *Eur. J. Gastroenterol. Hepatol.* 16 (2004) 201–205.
- [14] M. Bitar, A. Soweid, R. Mahfouz, G. Zaatari, N. Fuleihan, Is *Helicobacter pylori* really present in the adenoids of children? *Eur. Arch. Otorhinolaryngol.* 262 (2005) 987–992.
- [15] M. Bitar, R. Mahfouz, A. Soweid, et al., Does *Helicobacter pylori* colonize the nasopharynx of children and contribute to their middle ear disease? *Acta Otolaryngol.* 126 (2006) 154–159.
- [16] L. Marzio, D. Angelucci, L. Grossi, M.G. Diodoro, E. Di Campli, L. Cellini, Anti-*Helicobacter pylori* specific antibody immunohistochemistry improves the diagnostic accuracy of *Helicobacter pylori* in biopsy specimen from patients treated with triple therapy, *Am. J. Gastroenterol.* 93 (1998) 223–226.
- [17] B. Jelavic, M. Bevanda, M. Ostojic, M. Leventic, M. Vasilj, E. Knezevic, Tonsillar colonization is unlikely to play important role in *Helicobacter pylori* infection in children, *Int. J. Pediatr. Otorhinolaryngol.* 71 (2007) 585–590.
- [18] G. Di Bonaventura, G. Catamo, M. Neri, G. Neri, R. Piccolomini, Absence of *Helicobacter pylori* in tonsillar swabs from dyspeptic patients, *New Microbiol.* 23 (2000) 445–448.
- [19] A. Pitkaranta, K.L. Kolho, H. Rautelin, *Helicobacter pylori* in children who are prone to upper respiratory tract infections, *Arch. Otolaryngol. Head Neck Surg.* 131 (2005) 256–258.
- [20] G. di Bonaventura, M. Neri, G. Neri, G. Catamo, R. Piccolomini, Do tonsils represent an extragastric reservoir for *Helicobacter pylori* infection, *J. Infect.* 42 (2001) 221–222.
- [21] M.Y. Cirak, A. Ozdek, D. Yilmaz, U. Bayiz, E. Samim, S. Turet, Detection of *Helicobacter pylori* and its CagA gene in tonsil and adenoid tissues by PCR, *Arch. Otolaryngol. Head Neck Surg.* 129 (2003) 1225–1229.
- [22] M. Sugimoto, J.Y. Wu, S. Abudayyeh, et al., Caution regarding PCR detection of *Helicobacter pylori* in clinical or environmental samples, *J. Clin. Microbiol.* 47 (2009) 738–742.