

Molecular Analysis of c-Kit and PDGFRA in GISTs Diagnosed by EUS

Ana L. Gomes, BSc,¹ Ricardo H. Bardales, MD,^{2*} Fernanda Milanexi, MD,^{1,3} Rui M. Reis, PhD,¹ and Fernando Schmitt, MD, PhD^{1,3,4}

Key Words: Endoscopic ultrasound-guided fine-needle aspiration; c-Kit; Platelet-derived growth factor- α ; PDGFRA; Gastrointestinal stromal tumor; GIST; Mutations

DOI: 10.1309/M1EC8JE9ACAMJACU

Abstract

Gastrointestinal stromal tumors (GISTs) are characterized by overexpression and mutations of c-Kit. Approximately 80% of c-Kit mutations occur in exon 11, being a response factor to imatinib (Gleevec) therapy. Mutations of platelet-derived growth factor receptor- α (PDGFRA) are observed in a subset of GISTs lacking c-Kit mutations.

We aimed to assess whether c-Kit and PDGFRA mutation analysis of GISTs obtained by endoscopic ultrasound-guided fine-needle aspiration (EUS-FNA) could be routinely performed. Mutation analysis of c-Kit hotspot exons (9, 11, 13, and 17) and PDGFRA hotspot exons (12 and 18) was performed in aspirates of 33 GISTs and 18 non-GIST mesenchymal tumors.

Of the GIST cases, 19 (58%) of 33 contained a mutation in exon 11, 1 (3%) in exon 9, and none in exons 13 and 17. No activating c-Kit mutations were identified in non-GIST cases. No PDGFRA mutation was detected.

Mutation analysis is possible in these FNA cell blocks and can assist in the diagnosis and therapeutic decisions in GIST cases.

Gastrointestinal stromal tumors (GIST) are the most common mesenchymal tumors of the gastrointestinal tract, with an annual incidence of 10 to 20 cases per million.¹ GISTs are rarely found outside the gastrointestinal tract, being most commonly found in the stomach (40%-70%), small intestine (20%-50%), colon and rectum (5%-15%), and esophagus (<2%).² These tumors are thought to arise from interstitial cells of Cajal owing to their similar positive immunoreactivity for CD34 and CD117 (c-Kit), and to their lack of immunoreactivity for desmin and S-100 protein. Interstitial cells of Cajal are spindle-shaped cells located throughout the gastrointestinal tract. They are specialized cells of the enteric nervous system forming a network in the myenteric plexus layer, which primarily controls gastrointestinal tract motility.³ Before 1998, almost all GISTs were misdiagnosed as smooth muscle tumors such as leiomyomas, leiomyosarcomas, or leiomyoblastomas.^{4,5} In 1998, Hirota et al⁶ described the expression of c-Kit protein as an incontestable feature of GISTs, further separating them from other gastrointestinal mesenchymal tumors. At present, GIST is considered to be a specific category different from true smooth muscle tumors and neurogenic tumors.⁷

c-Kit belongs to the class III receptor tyrosine kinases (RTKs), together with platelet-derived growth factor receptor- α (PDGFRA), colony-stimulating factor-1 receptor (CSF-1-R), vascular endothelial growth factor receptors 1 and 2 (Flt-1 and Flk-1, respectively), Flk-2, and Flt-4. The RTKs are characterized by the presence of an extracellular domain, a transmembrane domain, a juxtamembrane domain, and an intracellular domain where the 2 kinase domains are lodged.⁸ Activation of c-Kit occurs when by the binding of stem cell factor, the receptor homodimerizes and experiences conformational

transformations that lead to the activation of the kinase domains. These, in turn, transphosphorylate the tyrosine residues of the opposing homodimerized receptor, allowing its association with substrates of various kinds.⁸ Like the majority of RTKs, *c-Kit* has been attributed many physiologic functions such as cell survival, proliferation, differentiation, adhesion, and apoptosis by signaling through the MAP kinase, PI3-kinase, and JAK/STAT pathways.⁹ *c-Kit* signaling is essential for normal erythropoiesis, lymphopoiesis, gametogenesis, and melanogenesis and for the correct development and function of mast cells.¹⁰ A dysfunctional activation of this RTK, therefore, has been involved in diverse neoplasias such as mastocytosis/mast cell leukemia,¹¹ germ cell tumors,¹² small cell lung carcinoma,¹³ acute myeloid leukemia,¹⁴ neuroblastoma,¹⁵ melanoma,¹⁶ ovarian carcinoma,¹⁷ and breast carcinoma,¹⁸ besides GISTs.^{2,3,7,8}

Mutations of the *c-Kit* oncogene are the major genetic alterations in GISTs. There is a broad spectrum of *c-Kit* mutations in GISTs, ranging from 30% to 90%, and *c-Kit* status can constitute a prognostic factor for survival.¹⁹ Most of the mutations are located in the juxtamembrane domain (exon 11), followed by the extracellular domain (exon 9), and seldom are in the kinase domains (exon 13 and 17). Recently, Heinrich et al²⁰ showed that about 35% of GISTs lacking *c-Kit* mutations have intragenic activation mutations in *PDGFRA*, the most common, located in exons 12, 14, and 18. Mutations of *c-Kit* and *PDGFRA* seem to be mutually exclusive oncogenic events in GISTs.²⁰

Until recently, the prognosis of patients with GISTs was poor owing to its frequent recurrence and resistance to chemotherapy and radiotherapy regimens.²¹ The development and current treatment with specific RTK inhibitors is changing this scenario. Imatinib mesylate (Gleevec) is a selective inhibitor of RTKs; by competing with the adenosine triphosphate for its binding site, preventing further phosphorylation of signaling molecules downstream of the receptor, it is responsible for abnormal viability and proliferation signals in these cells.²² Several studies have linked different responses to the drug with *c-Kit* alterations. In particular, tumors harboring exon 11 *c-Kit* mutations are more likely to respond to imatinib therapy than those with exon 9 *c-Kit* mutations or no detectable mutation.²³ On the other hand, some mutations, such as D816V, are linked to imatinib response.²³ Currently, imatinib is used for the treatment of patients with *c-Kit* (CD117)-positive GIST with unresectable and/or metastatic malignant tumor.²⁴ Besides imatinib, another RTK inhibitor, sunitinib (Sutent), has been recently approved for the treatment of patients with GIST whose disease has progressed or who are unable to tolerate treatment with imatinib.²⁵

It is a fact that obtaining an accurate diagnosis is of utmost importance for correct treatment; an earlier diagnosis is crucial for prompt therapy. Endoscopic ultrasound-guided fine-needle aspiration (EUS-FNA) biopsy has been increasingly

used for the assessment of diverse intra-abdominal and intrathoracic tumors.^{26,27}

EUS-FNA biopsy not only allows for a meticulous representation of extramural and intramural structures of the gastrointestinal tract but also permits tissue sampling from masses in these locations.^{28,29} In the present study, we aimed to perform molecular analysis of *c-Kit* and *PDGFRA* genes in formalin-fixed, paraffin-embedded cell blocks obtained by EUS-FNA biopsy from GISTs and non-GISTs. The feasibility of such analysis would lead to a more precise diagnosis and therapeutic decision in routine management of patients with GISTs (particularly patients with recurrent or imatinib-resistant tumors).

Materials and Methods

Tissue Samples

Between January 2000 and December 2005, 85 patients with intramural gastrointestinal mesenchymal tumors were diagnosed by EUS-FNA biopsy at Hennepin County Medical Center, Minneapolis, MN. These tumors were preclassified by the pathology department as 48 GISTs, 5 schwannomas, 27 leiomyomas, and 5 nonspecified spindle cell tumors.

Original classification of the tumors was based on immunocytochemical analysis for GIST (CD117+/CD34+), schwannoma (S-100 protein+/CD117-), and leiomyoma (actin+/desmin+/CD117-). Case selection for the study was based on specimen availability for molecular and immunocytochemical analysis. Cell blocks of the initial 85 cases were obtained; however, molecular analysis and complete repeated immunocytochemical analysis were possible in 49 cases, and in 2 cases, it was possible to perform only molecular analysis. Original and repeated immunocytochemical results were compared. **Table 1** lists the 51 cases, which included 33 GISTs, 14 leiomyomas, and 4 schwannomas. The mean age of patients was 62.5 years (range, 26-92 years). Of the patients, 20 (39%) were women and 31 (61%) were men. Topographically, 12 tumors (24%) were located in the esophagus, 35 (69%) were gastric, and 4 (8%) were located in the small intestine. The mean tumor size documented by EUS was 33.9 mm (range, 11-80 mm). The clinicopathologic features of the cases are summarized in Table 1.

c-Kit Immunocytochemical Studies

Immunocytochemical studies of the 51 cases were performed in material obtained from cell blocks. The procedure was performed according to streptavidin-biotin-peroxidase complex principle, using rabbit polyclonal antihuman antibodies raised against *c-Kit* (clone A 4502, dilution 1:50; DAKO, Carpinteria, CA), as previously described.³⁰ Briefly, deparaffinized and rehydrated slides were subjected to 10

Table 1
Clinical Data for 51 Patients

Case No./Sex/Age (y)	Size by EUS (mm)	Location	CD117	c-Kit Mutations	Final Diagnosis
1/F/67	Unknown	Gastric	+	Exon 11: V555V, V560D, L576F	GIST
2/M/77	27	Gastric	+	Exon 11: Y553N	GIST
3/F/82	35	Gastric	+	Exon 11: V560D	GIST
4/M/92	48	Gastric	+	Exon 11: 563del574, insGGGTCC	GIST
5/F/70	20	Gastric	+	Exon 11: 557del558	GIST
6/M/69	63	Gastric	+	Exon 11: V560D	GIST
7/M/72	55	Gastric	+	Wild type	GIST
8/M/47	Unknown	Gastric	+	Exon 11: V560D	GIST
9/F/75	13	Gastric	+	Exon 11: V560D	GIST
10/F/72	24	Intestine	+	Wild type	GIST
11/F/82	35	Intestine	+	Wild type	GIST
12/M/79	37	Esophagus	+	Exon 11: 579dup582, E583E, F584N	GIST
13/F/86	36	Gastric	+	Wild type	GIST
14/M/64	26	Gastric	+	Exon 11: W557C, 558del560	GIST
15/M/66	48	Gastric	-	Wild type	GIST
16/F/48	56	Gastric	-	Wild type	GIST
17/M/84	25	Gastric	-	Wild type	GIST
18/M/68	10	Gastric	-	Wild type	GIST
19/F/51	41	Gastric	+	Wild type	GIST
20/F/51	47	Gastric	+	Exon 11: V559del	GIST
21/F/36	30	Gastric	+	Wild type	GIST
22/M/78	13	Gastric	-	Wild type	GIST
23/M/76	23	Gastric	NA	Exon 11: N567S	GIST
24/F/65	57	Gastric	+	Exon 11: W557C, 558del560	GIST
25/F/82	43	Gastric	-	Wild type	GIST
26/M/69	13	Gastric	-	Wild type	GIST
27/M/52	76	Intestine	NA	Exon 11: V559A	GIST
28/M/49	80	Gastric	+	Exon 11: 554del556	GIST
29/M/89	18	Gastric	+	Exon 11: 554del556	GIST
30/M/54	15	Gastric	+	Exon 11: V560D	GIST
31/M/64	40	Gastric	+	Exon 11: 555del559	GIST
32/F/44	28	Gastric	+	Exon 9: 502dup503	GIST
33/M/59	33	Gastric	+	Exon 11: 557del558	Suggestive of GIST
34/M/57	46	Esophagus	-	Exon 11: L590L	Leiomyoma
35/M/74	11	Gastric	-	Wild type	Leiomyoma
36/M/52	69	Esophagus	-	Wild type	Leiomyoma
37/M/41	28	Esophagus	-	Wild type	Schwannoma
38/M/48	74	Gastric	-	Exon 11: E561E	Leiomyoma
39/M/79	25	Gastric	-	Wild type	Leiomyoma
40/M/50	22	Esophagus	-	Wild type	Leiomyoma
41/F/54	17	Esophagus	-	Wild type	Leiomyoma
42/M/65	30	Gastric	-	Wild type	Leiomyoma
43/M/26	45	Esophagus	-	Wild type	Leiomyoma
44/F/72	18	Esophagus	-	Wild type	Schwannoma
45/M/49	17	Esophagus	-	Wild type	Leiomyoma
46/F/41	41	Esophagus	-	Wild type	Leiomyoma
47/M/47	32	Esophagus	-	Wild type	Leiomyoma
48/F/62	34	Esophagus	-	Wild type	Leiomyoma
49/F/61	14	Gastric	-	Wild type	Leiomyoma
50/F/36	13	Gastric	-	Wild type	Schwannoma
51/M/52	33	Intestine	-	Wild type	Schwannoma

EUS, endoscopic ultrasound; GIST, gastrointestinal stromal tumor; NA, not available; +, positive; -, negative.

minutes' incubation in 3% hydrogen peroxide in methanol to inhibit endogenous peroxidase. No antigen retrieval was used. After incubation with the primary antibody at room temperature for 2 hours, the secondary biotinylated goat anti-polyvalent antibody was applied for 10 minutes, followed by incubation with streptavidin-peroxidase complex. The immune reaction was visualized with 3,3'-diaminobenzidine (DAB) as the chromogen (Ultravision Detection System Anti-polyvalent, HRP/DAB; Lab Vision, Fremont, CA). Appropriate

positive and negative control samples were included in each run: a case of gastrointestinal stromal tumor with previously characterized c-Kit overexpression was used as a positive control sample. For negative control samples, primary antibodies were omitted. All sections were counterstained with hematoxylin.

DNA Isolation

Selected areas that contained at least 85% of tumor tissue were microdissected under microscopic view and collected

into a microfuge tube using a sterile needle (Neolus, 25 gauge, 0.5 mm, Terumo, Tokyo, Japan). The dissected tissue was deparaffinized by a serial extraction with xylol and ethanol (100%-70%-50%) and allowed to air dry. DNA was extracted using the QIAamp DNA Micro Kit (Qiagen, Hilden, Germany) following the manufacturer's instructions. DNA samples were stored at -20°C for further analysis.

c-Kit Mutation Analysis

c-Kit mutation analysis was performed as previously described.³¹ DNA was subjected to polymerase chain reaction (PCR) amplifications of exons 9, 11, 13, and 17 of the *c-Kit* gene. Briefly, the PCR reaction was carried out in a final volume of 25 μL under the following conditions: 1 \times Buffer (Bioron, Ludwigshafen, Germany); 1.5 mmol/L of magnesium chloride (Bioron); 200 $\mu\text{mol/L}$ of deoxyribonucleotide triphosphates (dNTPs; Fermentas, Burlington, Canada); 0.5 $\mu\text{mol/L}$ of primers (DNA Technology, Aarhus, Denmark; previously described by Corless et al³), and 1 U of Super Hot *Taq* Polymerase (Bioron).

PCR amplification was followed by single-strand conformation polymorphism (SSCP) analysis of exons 9, 13, and 17 of *c-Kit* in a 1 \times mutation detection enhancement gel (Cambrex, North Brunswick, NJ), with 6% glycerol added in the exon 13 analysis. Twenty microliters of the PCR product were incubated at 95°C for 10 minutes with an equal volume of formamide loading buffer (98% formamide, 10 mmol/L of EDTA, and 1 mg/mL of bromophenol blue and xylene cyanol). SSCP gels were run at 20°C for exons 9, 13, and 17. Samples with an SSCP pattern different from the normal pattern were directly sequenced. Direct sequencing of exons 9, 11, and 13 was done with the following internal primer set: 5'-AGCCAGGGCTTTTGTCTTCT-3' (forward, exon 9); 5'-CAGAGCCTAAACATCCCCTTA-3' (reverse, exon 9); 5'-GTGCTCTAATGACTGAGACAATAAT-3' (forward, exon 11); 5'-ACCCAAAAAGGTGACATGGA-3' (reverse, exon 11); 5'-CATCAGTTTGCCAGTTGTGC-3' (forward, exon 13); and 5'-ACACGGCTTTACCTCCAATG-3' (reverse, exon 13). All cases were confirmed twice with new PCR amplification, direct sequencing, and SSCP analysis.

PDGFRA Mutation Analysis

Tumors with a wild-type *c-Kit* gene were further screened for hotspot *PDGFRA* mutations (exons 12 and 18) as previously described.³⁰ Briefly, the PCR reaction was carried out in a final volume of 25 μL , under the following conditions: 1 \times Buffer (Bioron); 1.5 mmol/L of magnesium chloride (Bioron); 200 $\mu\text{mol/L}$ of dNTPs (Fermentas); 0.5 $\mu\text{mol/L}$ of primers (DNA Technology; previously described by Corless et al³), and 1 U of Super Hot *Taq* Polymerase (Bioron). PCR was followed by direct sequencing. Direct sequencing of both exons was done with the following internal primer set:

5'-CCTAGTCGGTCAGAACGT-3' (forward, exon 18); 5'-GACCAGTCCGAGTAGGAG-3' (reverse, exon 18); 5'-CTCTGGTGCCTGGGACTTT-3' (forward, exon 12); and 5'-AAAGGGAGTCTTGGGAGTT-3' (reverse, exon 12). Direct sequencing results were confirmed with a new PCR amplification and direct sequencing procedure.

Statistical Analysis

Clinical and molecular data were analyzed with StatView for Windows, version 5.0. A *P* value less than .05 was considered significant.

Results

Immunocytochemical Results

All non-GIST cases were immunonegative for CD117 (*c-Kit*). The tumor cells were immunoreactive for S-100 protein or actin and desmin in all schwannoma and leiomyoma cases, respectively (data not shown). In 2 cases (cases 23 and 27), the immunostaining was not interpretable owing to technical artifacts (Table 1). Immunoreactivity for CD117 was detected in a majority of the remaining 31 tumors preclassified as GISTs. In 77% (24/31) of GIST tumors, CD117 positivity was strongly present at the membrane and diffuse in the cytoplasm **Image 1**. CD117 was negative in 7 (23%) of 31 tumors preclassified as GISTs.

c-Kit Screening

PCR amplification and DNA sequencing revealed exon 11 mutation in 19 (58%) of 33 GISTs and exon 9 mutation in 1 GIST (3%). Among the GISTs with *c-Kit* mutations, sequence analysis of exon 11 showed in-frame deletions of 3 to 33 base pairs (9/19 tumors [47%]) alone (6 tumors [67%]) or associated with missense mutations or insertions (3 tumors [33%]), single base substitutions (9 tumors [47%]), and an in-frame insertion associated with point mutation (1 tumor [5%]). A case-by-case listing of these mutations is shown in **Table 2** and **Table 3**. The exon 9 sequence alteration consisted of Ala-Tyr duplication between codons 502 and 503. No exon 13 or exon 17 mutations were detected. Of 33 GISTs, 13 (39%) had wild-type *c-Kit*. In non-GIST cases, all but 2 had no identifiable *c-Kit* sequence alteration **Image 2**. In these 2 cases, a single base substitution translated to a silent mutation in both cases (leiomyomas), not changing the codified amino acid.

PDGFRA Mutation Screening

No *PDGFRA* activating mutations were detected in the *c-Kit* wild-type-bearing tumors. Mutational analysis of exon 18 showed the presence of a base insertion in the intron preceding exon 18, ie, IVS18-50insA. Mutation analysis of exon 12

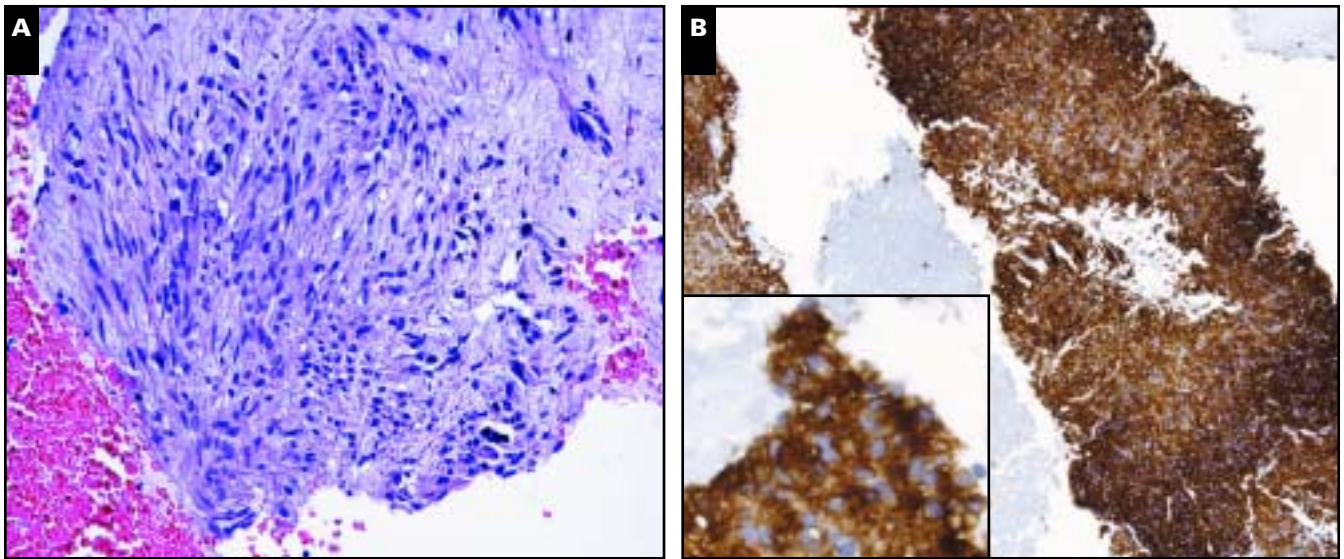


Image 1 **A**, A cell block obtained from fine-needle aspiration (FNA) biopsy of a gastrointestinal stromal tumor (GIST) showing spindle-cell morphologic features (H&E, $\times 200$). **B**, Strong positivity for CD117 in a cell block obtained from FNA biopsy of a GIST ($\times 100$). Inset, Cytoplasmic and membrane reactivity and absence of nuclear staining ($\times 400$).

showed the presence of a homozygous substitution of an adenine for a guanine (polymorphism R) in the third position of the codon coding for proline 567. All cases analyzed showed both polymorphisms.

Statistical Analysis

Tumor type was statistically correlated with patient age ($P = .022$); the median age for patients with GISTs was 67.8

years; with leiomyoma, 55.8 years; and with schwannoma, 43.0 years. Statistical significance was maintained when comparing GISTs with other tumors ($P = .013$).

Tumor type was also statistically correlated with common gastric topography ($P < .0001$), CD117 expression ($P < .001$), and presence of a *c-Kit* mutation ($P = .0105$). All cases with mutated *c-Kit* were preclassified as GIST tumors. For GIST cases, expression of CD117 was correlated with presence or

Table 2
Amino Acid Sequence of Exon 11 of Wild-Type and Mutated c Protein*

	550	560	570	580
Wild type	KPMYEVQWKV	VEEINGNNYV	YIDPTQLPYD	HKWEFPRNRL
Case No.				
1	KPMYEVQWKV	DEEINGNNYV	YIDPTQFPYD	HKWEFPRNRL
2	KPMNEVQWKV	VEEINGNNYV	YIDPTQNPYD	HKWEFPRNRL
3	KPMYEVQWKV	DEEINGNNYV	YIDPTQLPYD	HKWEFPRNRL
4	KPMYEVQWKV	VEE_____	____QLPYD	HKWEFPRNRL
5	KPMYEVQ__V	VEEINGNNYV	YIDPTQLPYD	HKWEFPRNRL
6	KPMYEVQWKV	DEEINGNNYV	YIDPTQLPYD	HKWEFPRNRL
8	KPMYEVQWKV	DEEINGNNYV	YIDPTQLPYD	HKWEFPRNRL
9	KPMYEVQWKV	DEEINGNNYV	YIDPTQLPYD	HKWEFPRNRL
12	KPMYEVQWKV	VEEINGNNYV	YIDPTQLPYD	HKWDHKKWENP
14	KPMYEVQC__	_EEINGNNYV	YIDPTQLPYD	HKWEFPRNRL
20	KPMYEVQWK_	VEEINGNNYV	YIDPTQLPYD	HKWEFPRNRL
23	KPMYEVQWKV	VEEINGNSYV	YIDPTQLPYD	HKWEFPRNRL
24	KPMYEVQC__	_EEINGNNYV	YIDPTQLPYD	HKWEFPRNRL
27	KPMYEVQWKA	VEEINGNNYV	YIDPTQLPYD	HKWEFPRNRL
28	KPMY___WKV	VEEINGNNYV	YIDPTQPPYD	HKWEFPRNRL
29	KPMY___WKV	VEEINGNNYV	YIDPTQLPYD	HKWEFPRNRL
30	KPMYEVQWKV	DEEINGNNYV	YIDPTQLPYD	HKWEFPRNRL
31	KPMYE_____	VEEINGNNYV	YIDPTQFPYD	HKWEFPRNRL
33	KPMYEVQ__V	VEEINGNNYV	YIDPTQLPYD	HKWEFPRNRL

* Underscore indicates deleted amino acid residues.

Table 3
Amino Acid Sequence of Exon 9 of Wild-Type and Mutated c-Kit Protein

	495	600	510
Wild type	NDVGK	TSAYFNFAFK	GN
Case 32	NDVGK	TSAYAYFNFA	FK

absence of *c-Kit* mutations ($P < .003$). All immunonegative GIST cases had wild-type *c-Kit*, and all cases with mutated *c-Kit* expressed CD117.

No other statistical significance was obtained for any other variables.

Discussion

GISTs comprise a broad clinical spectrum from benign, incidentally detected intramural nodules to severe, locally aggressive, or metastatic malignant tumors. Because they are generally resistant to chemotherapy and radiotherapy, the preferred treatment modality for GIST is surgery. The intensive cancer research during the last decade demonstrated the fundamental role of RTK, in particular kit in the pathogenesis of GIST. *c-Kit* has become more than just a diagnostic marker; it is actually of great value for therapeutic approaches given the development of RTK inhibitors such as imatinib.^{32,33}

In the present study, we have shown that 77% of GISTs strongly and diffusely express *c-Kit*, irrespective of tumor topography or patient age or sex. Although several studies indicate that 95% to 100% of GIST cases express *c-Kit*, lower

expression levels have been reported in Australian (78%) and Scandinavian studies (85%).^{34,35} Such differences in protein expression levels are probably due to distinct methods and population diversity. We identified *c-Kit* mutations in 61% of GIST cases, in accordance with previously published ranges (30%-90%).

Nearly 95% (19/20) of *c-Kit*-mutant tumors carried exon 11 mutations. In 84% of these cases (16/19), mutations were clustered in the region between codons 550 and 561, known to be the most frequently altered section of exon 11, with 31% affecting codons 557 or 558. These 2 codons are reported to be associated with the metastatic behavior of GISTs.³⁶ Besides having detected a single case bearing a known duplication in exon 9 (502dup503), no mutations were found in exon 13 or 17 (kinase domains). Interestingly, although reported to be associated with an intestinal localization, the GIST case bearing a *c-Kit* exon 9 mutation had a gastric location. Indeed, 88% of our FNA-GIST series was topographically classified as gastric. No colonic GISTs were identified in this study, and this is most likely because most EUSs were done in the upper gastrointestinal tract.

Even though it is well accepted that approximately 20% of *c-Kit* wild-type-bearing GISTs harbor *PDGFRA* mutations, none was detected in the present series. More interesting is that despite the reported association between *PDGFRA* mutants and gastric location and despite the location of more than 85% of *c-Kit* wild-type-bearing GISTs in the stomach, no genetic alteration in *PDGFRA* exon 12 or 18 was detected. Although methodological reasons cannot be ruled out, our experience has shown a frequency of 31% of *PDGFRA* mutations in Portuguese *c-Kit* wild-type GISTs (personal observation).

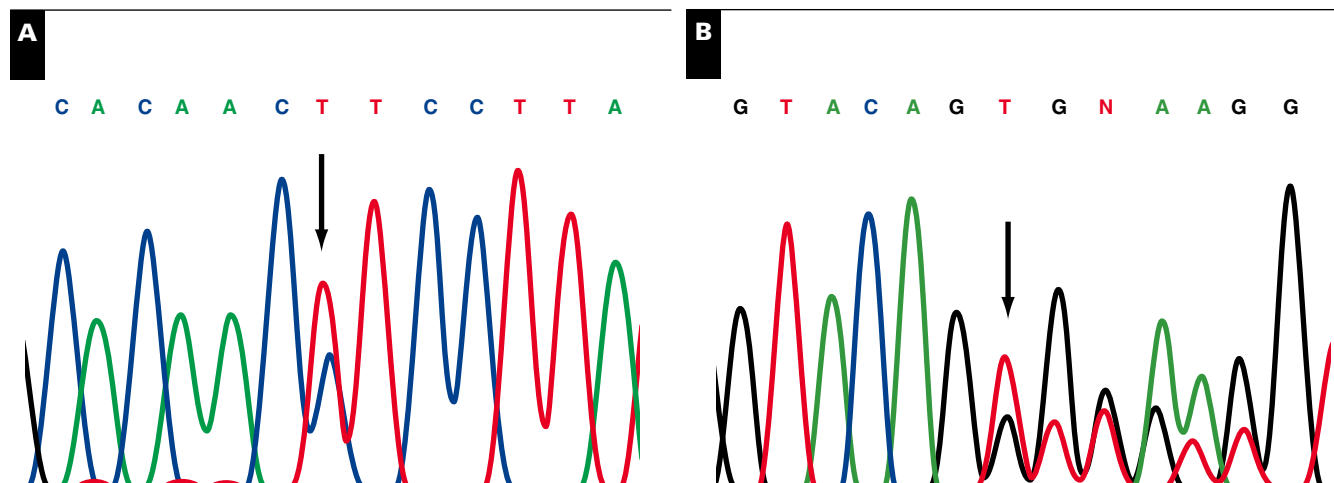


Image 2 Sequencing analysis of 2 gastrointestinal stromal tumor cases representing the DNA sequence of exon 11 of *c-Kit*. Each nucleotide is represented by 1 color. **A** (Case 28), Arrow indicates substitution of a thymine by a cytosine (L576P). **B** (Case 33), Arrow indicates beginning of deleted DNA sequencing (557del558).

Imatinib was initially designed to inhibit the bcr/abl fusion kinase protein in chronic myeloid leukemia and was later discovered to be effective against GISTs with *c-Kit* and *PDGFRA* mutations. Response to imatinib therapy is dependent on the presence of activating mutations in either class III RTK; however, some patients have tumors with imatinib-resistant mutations. Specifically, mutations affecting the juxtamembrane domain (exon 11; partial response in 83.5%) or the extracellular domain (exon 9; partial response in 47.8%) are responsive to imatinib, whereas mutations in the other 2 *c-Kit* hotspots are predominantly resistant, ie, V654A and W670I (in kinase domain 1, exon 13) and D816V and T823D (in kinase domain 2, exon 17).^{19,37,38}

Regarding the *PDGFRA* mutation, the majority of alterations affecting codon 842 in exon 18 (corresponding to exon 17 of *c-Kit*) are known to be imatinib-resistant.^{1,32} Even so, approximately 40% of patients with GISTs lack activating mutations in either RTK, and most are consequently not responsive to imatinib.^{1,32} In early 2006, the US Food and Drug Administration approved a new RTK inhibitor, sunitinib (Sutent) for the treatment of patients with GIST whose disease has progressed or who are unable to tolerate treatment with imatinib.²⁵ This recent RTK inhibitor has opened new doors to other RTK-overexpressing tumors in view of the fact that positive therapy responses are obtained in the presence of the wild-type RTK or the previously described imatinib-resistant mutants.³⁹ Progress has made it necessary to accurately define the type of mutation present in these tumors.

EUS-FNA, a less costly, less risky, and less invasive strategy than several other options, is an increasingly used procedure for the diagnosis of gastrointestinal tumors. However, most studies comprise small series and lack molecular analysis of the key pathogenetic oncogenes (*c-Kit* and *PDGFRA*).^{26,28,40-42} In the present study, we have shown that GISTs could be diagnosed preoperatively on EUS-FNA specimens. In addition to immunocytochemical studies, molecular analysis can be done on formalin-fixed, paraffin-embedded cell-block material obtained from these aspirates, avoiding more invasive diagnostic procedures to obtain a tissue diagnosis.

Nowadays, with 2 RTK inhibitors available, there is an imperative need for redefining GIST diagnosis and including molecular analysis of *c-Kit* and *PDGFRA* in the current diagnostic protocol so as to better and more quickly establish the specific therapeutic approach to use for a particular patient. We are unquestionably taking one step forward in the diagnosis of GIST by making the molecular analysis routinely feasible with a small sample.

From the ¹Life and Health Sciences Research Institute (ICVS), School of Health Sciences, University of Minho, Braga, Portugal; ²Hennepin County Medical Center, Minneapolis, MN; ³IPATIMUP, Institute of Molecular Pathology and Immunology of the University of Porto, and ⁴Medical Faculty of the University of Porto, Porto, Portugal.

Supported in part by NOVARTIS Oncology. Ana L. Gomes is recipient of fellowship grant SFRH/BI/15257/2004 from FCT, Lisbon, Portugal.

Address reprint requests to Dr Schmitt: Institute of Molecular Pathology and Immunology, University of Porto, R. Dr. Roberto Frias s/n, 4200 Porto, Portugal.

* Currently with Outpatient Pathology Associates, Sacramento, CA.

References

- Rubin BP. Gastrointestinal stromal tumours: an update. *Histopathology*. 2006;48:83-96.
- Joensuu H, Kindblom LG. Gastrointestinal stromal tumors: a review. *Acta Orthop Scand Suppl*. 2004;75:62-71.
- Corless CL, McGreevey L, Haley A, et al. KIT mutations are common in incidental gastrointestinal stromal tumors one centimeter or less in size. *Am J Pathol*. 2002;160:1567-1572.
- Monihan JM, Carr NJ, Sobin LH. CD34 immunoreactivity in stromal tumours of the gastrointestinal tract and in mesenteric fibromatosis. *Histopathology*. 1994;25:469-473.
- Miettinen M, Virolainen M, Maarit SR. Gastrointestinal stromal tumors: value of CD34 antigen in their identification and separation from true leiomyomas and schwannomas. *Am J Surg Pathol*. 1995;19:207-216.
- Hirota S, Isozaki K, Moriyama Y, et al. Gain-of-function mutations of c-kit in human gastrointestinal stromal tumors. *Science*. 1998;279:577-580.
- Hirota S. Gastrointestinal stromal tumors: their origin and cause. *Int J Clin Oncol*. 2001;6:1-5.
- Kitamura Y, Hirota S. Kit as a human oncogenic tyrosine kinase. *Cell Mol Life Sci*. 2004;61:2924-2931.
- Ronnstrand L. Signal transduction via the stem cell factor receptor/c-Kit. *Cell Mol Life Sci*. 2004;61:2535-2548.
- Roskoski R Jr. Structure and regulation of Kit protein-tyrosine kinase: the stem cell factor receptor. *Biochem Biophys Res Commun*. 2005;338:1307-1315.
- Arber DA, Tamayo R, Weiss LM. Paraffin section detection of the c-kit gene product (CD117) in human tissues: value in the diagnosis of mast cell disorders. *Hum Pathol*. 1998;29:498-504.
- Looijenga LH, de Leeuw H, van Oorschot M, et al. Stem cell factor receptor (c-KIT) codon 816 mutations predict development of bilateral testicular germ-cell tumors. *Cancer Res*. 2003;63:7674-7678.
- Rossi G, Cavazza A, Marchionni A, et al. Kit expression in small cell carcinomas of the lung: effects of chemotherapy. *Mod Pathol*. 2003;16:1041-1047.
- Crosier PS, Ricciardi ST, Hall LR, et al. Expression of isoforms of the human receptor tyrosine kinase c-kit in leukemic cell lines and acute myeloid leukemia. *Blood*. 1993;82:1151-1158.
- Uccini S, Mannarino O, McDowell HP, et al. Clinical and molecular evidence for c-kit receptor as a therapeutic target in neuroblastic tumors. *Clin Cancer Res*. 2005;11:380-389.
- Montone KT, van Belle P, Elenitsas R, et al. Proto-oncogene c-kit expression in malignant melanoma: protein loss with tumor progression. *Mod Pathol*. 1997;10:939-944.
- Raspollini MR, Amunni G, Villanucci A, et al. c-KIT expression and correlation with chemotherapy resistance in ovarian carcinoma: an immunocytochemical study. *Ann Oncol*. 2004;15:594-597.

18. Ulivi P, Zoli W, Medri L, et al. c-kit and SCF expression in normal and tumor breast tissue. *Breast Cancer Res Treat.* 2004;83:33-42.
19. Debiec-Rychter M, Dumez H, Judson I, et al. Use of c-KIT/PDGFRα mutational analysis to predict the clinical response to imatinib in patients with advanced gastrointestinal stromal tumours entered on phase I and II studies of the EORTC Soft Tissue and Bone Sarcoma Group. *Eur J Cancer.* 2004;40:689-695.
20. Heinrich MC, Corless CL, Duensing A, et al. PDGFRA activating mutations in gastrointestinal stromal tumors. *Science.* 2003;299:708-710.
21. Blay JY, Bonvalot S, Casali P, et al. Consensus meeting for the management of gastrointestinal stromal tumors: report of the GIST Consensus Conference of 20-21 March 2004, under the auspices of ESMO. *Ann Oncol.* 2005;16:566-578.
22. Baker DE. Imatinib mesylate. *Rev Gastroenterol Disord.* 2002;2:75-86.
23. Tam C, Merkel E, Canutescu AA, et al. Analysis of KIT mutations in sporadic and familial gastrointestinal stromal tumors: therapeutic implications through protein modeling. *Clin Cancer Res.* 2005;11:3668-3677.
24. Wilson J, Connock M, Song F, et al. Imatinib for the treatment of patients with unresectable and/or metastatic gastrointestinal stromal tumours: systematic review and economic evaluation. *Health Technol Assess.* 2005;9:1-142.
25. US Food and Drug Administration. FDA approves new treatment for gastrointestinal and kidney cancer [press release]. Rockville, MD: FDA; January 26, 2006. Available at: <http://www.fda.gov/bbs/topics/news/2006/NEW01302.html>. Accessed March 1, 2006.
26. Chhieng DC, Jhala D, Jhala N, et al. Endoscopic ultrasound-guided fine-needle aspiration biopsy: a study of 103 cases. *Cancer.* 2002;96:232-239.
27. Bardales RH, Stelow EB, Mallery S, et al. Review of endoscopic ultrasound-guided fine-needle aspiration cytology. *Diagn Cytopathol.* 2006;34:140-175.
28. Vander NM III, Eloubeidi MA, Chen VK, et al. Diagnosis of gastrointestinal tract lesions by endoscopic ultrasound-guided fine-needle aspiration biopsy. *Cancer.* 2004;102:157-163.
29. Stelow EB, Stanley MW, Mallery S, et al. Endoscopic ultrasound-guided fine-needle aspiration findings of gastrointestinal leiomyomas and gastrointestinal stromal tumors. *Am J Clin Pathol.* 2003;119:703-708.
30. Carvalho I, Milanezi F, Martins A, et al. Overexpression of platelet-derived growth factor receptor alpha in breast cancer is associated with tumour progression. *Breast Cancer Res.* 2005;7:R788-R795.
31. Reis RM, Martins A, Ribeiro SA, et al. Molecular characterization of PDGFR-α/PDGF-A and c-KIT/SCF in gliosarcomas. *Cell Oncol.* 2005;27:319-326.
32. Heinrich MC, Corless CL, Demetri GD, et al. Kinase mutations and imatinib response in patients with metastatic gastrointestinal stromal tumor. *J Clin Oncol.* 2003;21:4342-4349.
33. Zalcborg JR, Verweij J, Casali PG, et al. Outcome of patients with advanced gastro-intestinal stromal tumours crossing over to a daily imatinib dose of 800 mg after progression on 400 mg. *Eur J Cancer.* 2005;41:1751-1757.
34. Morey AL, Wanigsekera GD, Hawkins NJ, et al. C-kit mutations in gastrointestinal stromal tumours. *Pathology.* 2002;34:315-319.
35. Wasag B, Debiec-Rychter M, Pauwels P, et al. Differential expression of KIT/PDGFRα mutant isoforms in epithelioid and mixed variants of gastrointestinal stromal tumors depends predominantly on the tumor site. *Mod Pathol.* 2004;17:889-894.
36. Wardelmann E, Losen I, Hans V, et al. Deletion of Trp-557 and Lys-558 in the juxtamembrane domain of the c-kit protooncogene is associated with metastatic behavior of gastrointestinal stromal tumors. *Int J Cancer.* 2003;106:887-895.
37. Wardelmann E, Merkelbach-Bruse S, Pauls K, et al. Polyclonal evolution of multiple secondary KIT mutations in gastrointestinal stromal tumors under treatment with imatinib mesylate. *Clin Cancer Res.* 2006;12:1743-1749.
38. Frost MJ, Ferrao PT, Hughes TP, et al. Juxtamembrane mutant V560GKit is more sensitive to imatinib (STI571) compared with wild-type c-kit whereas the kinase domain mutant D816VKit is resistant. *Mol Cancer Ther.* 2002;1:1115-1124.
39. Carter TA, Wodicka LM, Shah NP, et al. Inhibition of drug-resistant mutants of ABL, KIT, and EGF receptor kinases. *Proc Natl Acad Sci U S A.* 2005;102:11011-11016.
40. Fu K, Eloubeidi MA, Jhala NC, et al. Diagnosis of gastrointestinal stromal tumor by endoscopic ultrasound-guided fine needle aspiration biopsy: a potential pitfall. *Ann Diagn Pathol.* 2002;6:294-301.
41. Willmore-Payne C, Layfield LJ, Holden JA. c-KIT mutation analysis for diagnosis of gastrointestinal stromal tumors in fine needle aspiration specimens. *Cancer.* 2005;105:165-170.
42. Padilla C, Saez A, Vidal A, et al. Fine-needle aspiration cytology diagnosis of metastatic gastrointestinal stromal tumor in the liver: a report of three cases. *Diagn Cytopathol.* 2002;27:298-302.