



Review

Morphometric and Connectivity White Matter Abnormalities in Obsessive Compulsive Disorder

Óscar F. Gonçalves, PhD^{a,b,c}, Sandra Carvalho, PhD^{a,b}, Jorge Leite, PhD^{a,b}, Ana Fernandes-Gonçalves, MD^d, Angel Carracedo, MD, PhD^e, Adriana Sampaio, MD, PhD^a

^aNeuropsychophysiology Lab, CIPsi, School of Psychology, University of Minho, Braga – Portugal;

^bSpaulding Center of Neuromodulation, Department of Physical Medicine & Rehabilitation, Spaulding Rehabilitation Hospital and Massachusetts General Hospital, Harvard Medical School, Boston, MA, USA;

^cDepartment of Applied Psychology, Bouvé College of Health Sciences, Northeastern University, Boston-USA; ^dCUF Porto Hospital, Department of Psychiatry, Porto – Portugal; ^eForensic Genetics Unit, Institute of Legal Medicine, Faculty of Medicine, University of Santiago de Compostela, Galicia-Spain

^fCUF Porto Hospital, Department of Psychiatry, Porto – Portugal;

^gForensic Genetics Unit, Institute of Legal Medicine, Faculty of Medicine, University of Santiago de Compostela, Galicia-Spain

*Corresponding author: Óscar F. Gonçalves, Neuropsychophysiology Lab, School of Psychology University of Minho, Campus de Gualtar 4710-057 Braga, Portugal Tel: +351 253 604 261; Fax: +351 253 604 658; Email: goncalves@psi.uminho.pt

Received Jul 7th, 2016; Revised Sept 12th, 2016; Accepted Oct 12th, 2016

Abstract

Two psychological mechanisms seem to be associated with the obsessive-compulsive cycle: (1) an emotional mechanism characterized by intense emotional arousal associated with intrusive thoughts of impending danger; (2) a cognitive mechanism exemplified by difficulties with inhibitory control. Several studies found more extensive cognitive deficits in Obsessive Compulsive Disorder (OCD) beyond problems of inhibitory control and emotional regulation, namely: visual-spatial processing and memory. Thus, there is now extensive research showing that alterations of these psychological mechanisms in OCD (i.e., inhibitory control, emotional regulation, working memory, and visual spatial processing) are associated with morphological gray matter alterations in widespread brain regions. More recently, researchers have started looking at white matter abnormalities in OCD. In this article we review the research looking at white matter morphometric and structural connectivity alterations in OCD. Altogether, while some contradictory findings are still present, there is now evidence for widespread white matter morphometric and connectivity abnormalities affecting major white matter tracts (superior longitudinal fasciculus, inferior fronto-occipital fasciculus, inferior longitudinal fasciculus, cingulum bundle, semioval center, internal capsule, different regions of the corpus callosum, thalamic radiation, uncinate fasciculus and optic radiation) as well as white matter in regions adjacent to gray matter structures (superior frontal gyrus, dorsolateral prefrontal medial frontal cortex; inferior frontal gyrus, caudate, insulate cortex, parietal cortex, supramarginal and lingual gyri, and thalamus). These white matter alterations may help explaining the diversity of OCD psychological impairments in inhibitory control, emotional regulation, memory and visual spatial processing.

Keywords: obsessive compulsive disorder; white matter; diffusion tensor imaging.

Citation: Óscar F. Gonçalves, PhD, Sandra Carvalho, PhD, Jorge Leite, PhD, Ana Fernandes-Gonçalves, MDd, Angel Carracedo, MD, PhD, Adriana Sampaio, MD, PhD. PPCR 2017, Jan-May;3(1).

Copyright: © 2017 Gonçalves O.F. et al. The Principles and Practice of Clinical Research is an open-access article distributed under the terms of the Creative Commons Attribution License, which allows unrestricted use, distribution, and reproduction in any medium, providing the credits of the original author and source

Introduction

Obsessive compulsive disorder (OCD) is characterized by the presence of intrusive unwanted thoughts, images, ideas, urges involuntarily entering consciousness (obsessions), which the individual tries to neutralize by repetitive behaviors (e.g., checking) or mental actions (e.g., praying) (compulsions). Two psychological mechanisms

seem to be associated with the obsessive-compulsive cycle: (1) an emotional mechanism characterized by intense emotional arousal associated with intrusive thoughts of impending danger; (2) a cognitive mechanism exemplified by difficulties with inhibitory control.

The intense emotional arousal reported by patients is probably the expression of an affective-motivational imbalance between the defensive (i.e., fear response) and

appetitive mechanisms (i.e., ingestion, copulation, and care giving responses) which may be responsible for a more extended emotional deregulation (Gonçalves, Soares, et al., 2015). Additionally, there is abundant evidence on the existence of executive functioning deficits particularly involving response inhibition (Snyder, Kaiser, Warren, & Heller, 2015). More recently, several studies suggest other cognitive deficits in OCD beyond executive functioning and emotional regulation, namely visual-spatial processing (S. N. Kim, Lee, Yoon, & Kwon, 2016) and memory (Jaafari et al., 2013).

There is now extensive research showing that alterations of these psychological mechanisms in OCD (i.e., inhibitory control, emotional regulation, working memory, and visual spatial processing) are associated with morphological gray matter alterations in widespread brain regions (Piras et al., 2015). Only recently, researchers have started looking at white matter abnormalities in OCD. This research effort was driven by two main reasons. First, given that several shape and volumetric abnormalities were found in widespread gray matter structures, one can easily infer that the structural connectivity between those structures may as well be altered. Second, shape abnormalities in gray matter territories may be suggestive of problems with development and maturation of the central system and as such thought to affect white matter pathways. Therefore, in this paper we discuss research involving the study of white matter alterations in OCD. We start by presenting data from morphometric studies on white matter alterations followed by a report of studies in white matter connectivity changes in OCD.

Evidence from White Matter Morphometric Studies

Based on clinical neuroimaging and chirurgical evidence of white matter abnormalities in regions associated with the cortico-striatal-thalamus-cortical (CSTC) pathways, Duran, Hoexter, Valente, Miguel, and Busatto, (2009) conducted a volumetric study looking for evidence of white matter abnormalities in the cingulum bundle (CB) and the anterior limb of the internal capsule (ALIC) in OCD patients when contrasted with healthy controls. ALIC is a pathway connecting the thalamus with the anterior cingulate and orbitofrontal cortices and a part of the CSTC loop involved in cognitive and emotional regulation (Sullivan, Zahr, Rohlfing, & Pfefferbaum, 2010). The CB is a major white-matter fasciculus connecting structures from the frontal, parietal and temporal cortices and thought to play a role in executive functioning as well as in emotional regulation (Heilbronner & Haber, 2014). Even though no significant differences were found between OCD and controls in terms of volumetric changes in CB and ALIC, a significant

decrease on overall white matter volumes was found for the OCD patients. Additionally, and in spite of the overall white matter reduction, an increase of white matter volume in the bilateral ALIC was found to be associated with symptomatic OCD severity, suggesting that these pathways may be implicated in OCD pathophysiology.

Another white matter region –septum pellucidum– has been suggested as an important marker of neurodevelopmental disruption in several psychiatric disorders, namely schizophrenia, schizotypal personality and affective disorders (Kwon et al., 1998). The closure of the septum pellucidum takes place around the 6th week of gestation and the non-union of both lamina results in the presence of a space referred to as cavum septum pellucidum (CSP). The presence or absence of CSP may represent a good indicator on the maturity of associated regions such as the corpus callosum and hippocampus (Hosseinzadeh, Luo, Borhani, & Hill, 2013). Chon, Choi, Kang, Jung, and Kwon (2010) carried out one study done so far trying to compare both the existence and the size of the CSP in OCD patients when compared with healthy controls. The results pointed out to the presence of significantly more CSP in OCD patients than healthy controls, which was associated with the severity of OCD symptomatology. However, contrary to what was found with other disorders (e.g., schizophrenia) no significant differences were found in the frequency of abnormally large CSP (greater than grade 2).

Another major white matter structure that has been object of morphometric studies is the corpus callosum (CC). CC is the core white commissure connecting the two brain hemispheres. Different regions of the CC (rostrum, genu, body, isthmus and splenium) connect different gray matter regions that have been associated with OCD pathophysiology. Park et al. (2011) conducted a study assessing both the area and the thickness of five different CC regions (i.e., CC1-CC5 – rostral to caudal) in OCD patients when compared with matched healthy controls. The authors found evidence for a significant increase of the overall CC area in the OCD sample, with significant enlargements of the CC1, CC2 and CC5 areas. Additionally, OCD patients were found to have a significantly thicker CC in the midbody and splenium regions. The evidence of volumetric and thickness alterations in the posterior CC (splenium) may be evidence of abnormal hemispheric connectivity between posterior temporal, parietal and occipital regions, which is consistent with findings on memory and visual spatial deficits in OCD. Volumetric alterations on more anterior genu CC1 regions confirm abnormalities in the white matter tracts connecting frontal regions that may be associated with most of prefrontal executive deficits present in OCD (e.g. cognitive flexibility, inhibitory

control, working memory). Volumetric changes in CC2 mid body may underlie problems with motor regulation in OCD.

Later, Lopez et al. (2013) did a manual segmentation of the five CC regions, comparing OCD and healthy matched controls. Contrasting to Park et al. (2011), this study found significant volume decreases in CC2 (mid body) and CC5 (splenium) regions in OCD patients. This was further confirmed by Di Paola et al. study (2013), in which OCD patients exhibited decreased density in anterior and posterior regions of the CC when comparing to healthy controls.

More recently Jose et al. (2015) in a study with medication naïve OCD patients compared with healthy controls found significant enlargement of both total CC as well as CC body parcellation. However, in this study the total CC volume, as well as isthmus and splenium regions, were negatively correlated with the compulsive scale of the Yale-Brown Obsessive Compulsive Scale (YBOCS)..

In sum, several morphological abnormalities have been reported in the CC as whole as well as its parcellations. However the results remain inconsistent, probably due to different segmentation methods used (e.g., manual versus automatic segmentation) and heterogeneity of the OCD samples (e.g. medicated versus treatment naïve).

Recent studies have been also exploring white matter morphometric abnormalities in regions adjacent to gray matter structures that were reported altered in OCD. A large scale mega-analysis on a multicenter consortium data base by de Wit et al. (2014) confirmed evidence of volumetric white matter alterations in regions associated with the CSTC territories, particularly medial, middle and inferior prefrontal regions along with the thalamus. However, recent studies have found evidence of abnormal white matter volumes to regions outside the CSTC. For example, a recent voxel based morphometry study by S.-E. Park and Jeong (2015) comparing OCD patients and healthy controls, observed white matter increases in both anterior (right dorsolateral prefrontal cortex, middle frontal gyrus) and posterior regions (precuneus, inferior parietal) consistently with gray matter studies (Piras et al., 2015). Again, these findings may contribute to explain the existence of executive, emotional and visual processes impairments reported in OCD patients.

Interesting to note that studies with pediatric OCD populations have been reporting widespread alteration in the white matter morphology across several brain regions. For example a study by Chen, Silk, Seal, Dally, and Vance (2013) comparing children with OCD and typical development controls, found decreased white matter in the bilateral cingulate, right frontal, bilateral occipital, right

parietal, left temporal cortices, as well as in the corpus callosum.

Concluding, morphometric alterations have been reported in several white matter tracks and regions, namely: (1) anterior limb of the internal capsule (potentially associated with emotional and cognitive regulation); (2) cavum septum (possible evidence of neurodevelopment abnormalities); (3) several regions of the corpus callosum (eventually associated with prefrontal, frontal, parietal and temporal interhemispheric connections abnormalities that may underlie executive, emotional, memory and visual spatial impairments in OCD); (4) alterations in white matter regions adjacent to the dorsolateral prefrontal cortex and the thalamus (possible contribution for executive impairments, particularly in terms of cognitive flexibility and inhibitory control); and (5) alterations in white matter regions adjacent to parietal regions (eventual associations with visual processing deficits).

Evidence from White Matter Connectivity Studies

In this section we discuss the main findings of the research looking at white matter connectivity using Diffusion Tensor Imaging (DTI). DTI is a neuroimaging method that allows the inference of microstructural connectivity alterations in the white matter fibers (Alexander, Lee, Lazar, & Field, 2007). DTI provides indexes of water diffusion in the brain tissue, allowing the estimation of several indexes, namely: Fractional anisotropy (FA), Mean diffusivity (MD), Radial diffusivity (RD), and Axial diffusivity (AD). FA is a measure describing the degree of water anisotropy diffusion in the brain. High FA values indicate a diffusion of water molecules along the fiber and are usually seen as synonymous with white matter integrity. On the contrary, MD expresses the existence of nonspecific barriers for free diffusion in the fiber. AD is a measure of longitudinal diffusion and seems to be a marker of axonal damage. Finally, RD is a measure of the transverse direction of diffusion and represents a good marker of altered myelination processes.

Consistent with morphometric studies, diffusion abnormalities were also found in the corpus callosum. For example, Saito et al. (2008) did a DTI study comparing the levels of mean diffusivity and fractional anisotropy in five regions of CC of OCD patients contrasted with healthy controls. While the OCD patients were found to show MD levels similar to the controls, a statistically significant reduction on FA was found for the OCD patients in the rostral region of the CC. Additionally, FA levels were negatively associated with OCD symptomatology. It is important to remind that the rostrum contains fibers connecting regions of the orbitofrontal cortex, suggesting the existence of

microstructural abnormalities in white matter tracks associated with difficulties in emotional and cognitive regulation.

Later, Oh et al. (2012), tried to dissociate callosal fibers projecting either towards the ventral or the dorsal regions of the prefrontal cortex in OCD and healthy controls. Significant lower FA levels were found in the orbitofrontal and dorsolateral prefrontal CC projections. Additionally, evidence for an integrity imbalance between ventral and dorsal projections was also reported (ventral-greater-than-dorsal asymmetry of FA values). This is an interesting finding suggesting that, independently of abnormalities in both pathways, differences of integrity may be present in tracts associated with emotional and cognitive regulation.

Abnormalities in diffusivity indexes have been reported in extended brain regions besides de the CC. For example, a DTI study by Szeszko et al. (2005) looked at patterns of white matter integrity as expressed by FA in OCD when compared with healthy controls. Consistent with the authors' hypotheses, significantly decrease of FA levels was found for OCD in the anterior cingulate white matter. Additionally, and consistent with similar findings for gray matter, decreased FA levels were observed in the posterior right cingulate, parietal lobes (bilateral supramarginal gyri), and occipital lobe (lingual gyrus). Most interestingly, the FA levels in these posterior regions correlated negatively with symptomatic severity. Diffusion alterations in the supramarginal gyrus and occipital cortex may be associated with visual spatial processing deficits. Of note is also the report of abnormalities on the lingual gyrus, a region of the brain that is associated with the processing of emotionally charged visual stimuli, suggesting that the processing of these type of stimuli may be impaired in OCD patients.

Contrasting with Szeszko et al. (2005) findings, Cannistraro et al. (2007) reported FA increases in the left cingulum bundle (CB) and in the anterior limb of the internal capsule (ALIC) and a FA decrease in the right CB. While the findings of a decreased FA in the right CB are consistent with the data reported above, the FA increase may be associated with an exaggerated coherence underlying functional hyperconnectivity between frontal and subcortical regions. It is worth pointing out that this study was conducted on a small sample of 8 OCD patients and 10 healthy controls. However, a study by Yoo et al. (2007) with drug naïve patients and matched healthy controls, partially confirmed these data, finding significant FA increases in several white matter regions such as the corpus callosum, internal capsule and white matter in the region of the right caudate. Interestingly enough, these differences disappeared after 12 weeks of treatment with citalopram.

Consistent with data from Yoo et al. (2007), Lochner et al. (2012) found evidence of significant increases in FA levels in the anterior limb of the internal capsule (bilaterally) near the body of the caudate region, contrasting with FA decreases in the right side of the anterior limb of the internal capsule close to the head of caudate. Again, this data seems to point to alterations of connectivity in major CSTC pathways with evidence of increased connectivity in striate regions (body of caudate region), and decreased connectivity in prefrontal projection pathways (head of caudate region). Additionally, a decrease MD was found in the left anterior cingulum and body of the right cingulum. Again, this data may point towards an increased structural connectivity in these regions. Contrasting with several studies reported previously, no significant differences were found between OCD and healthy controls in the genu of the CC and uncinata fasciculus.

Nakamae et al. (2008) tried to bring some light into contradictory results on increased versus decreased FA in OCD (e.g., anterior cingulum) by analyzing both the FA and the apparent diffusion coefficient - ADC (i.e., degree of apparent water diffusivity) across the whole brain. Overall, no regions were found with decreased FA levels in the OCD patients. On the contrary, and in line with the studies of Cannistraro et al. (2007) and Yoo et al. (2007), an increased FA was found for the OCD group in the bilateral semioval center extending to the subinsular white matter. No significant results were observed in the ADC index (other than a trend to an increased ADC in the left medial frontal gyrus). Along with Cannistraro et al. (2007), the authors interpreted their results in terms of increased connectivity in these brain regions which may be associated with most of the alterations of functional connectivity and symptomatic expression of OCD. As an example, the authors point out that the insula has been associated with emotional processing of disgust to which OCD patients seem to have higher sensitivity.

Menzies et al. (2008) extended the scope of previous studies by looking at white matter abnormalities in a DTI study comparing OCD patients with unaffected OCD relatives (first degree) and healthy controls. The results confirmed that decreased FA levels in certain regions co-existed with increased levels in other areas. More specifically, OCD patients were found to exhibit decreased FA in the right parietal region and increased FA in the right medial frontal region. Interestingly, those same findings were evident in first degree relatives of the OCD patients pointing out to the existence of white matter endophenotypes of increased risk for OCD. While the finding of increased FA on medial frontal regions seems to point, once again, to an hyperconnectivity in the frontal-subcortical circuits, the data on a decreased FA in the

parietal regions suggest a possible disconnectivity in these regions consistent with similar finding reported on morphometric white and gray matter studies, and possibly associated with visual spatial processing impairments.

Building on data presented above on the involvement of extended white matter abnormalities, Garibotto et al. (2010) looked at long intrahemispheric pathways connecting orbitofrontal with parietal and occipital regions. In this study, the FA levels and the principal diffusion direction - PDD (i.e., index revealing the structural anatomy through the analysis of the fiber direction within each voxel) of the most prominent intrahemispheric longer fiber tracts were analyzed in OCD patients and healthy controls. Significant decreased FA and alteration of the PDD levels were found in most of the pathways, namely the superior longitudinal fasciculus, the optic radiation, the inferior fronto-occipital fasciculus, along with the corpus callosum and the cingulate bundle. Additionally, FA levels were found to be significantly correlated with different symptomatic and neuropsychological measures. Particularly interesting was the correlation between FA levels and visual spatial processing measures (i.e., Trail Making - A), in line with the parietal white abnormalities reported by Menzies et al. (2008) and Szeszko et al. (2005).

One possible reason for the inconsistent results regarding white matter abnormalities is the diversity of DTI methodologies used. While most of the studies referred above used a voxel-based morphometry approach to DTI, Nakamae et al. (2011) suggested the analysis of FA using a Tract-Based Spatial Statistics - TBSS (Smith et al., 2006). In this study a sample of non-medicated OCD patients was compared with healthy controls. Contrary to some of the studies presented before, but consistent with Garibotto et al. (2010), no regions with increased FA were found. On the contrary, OCD patients had significantly lower FA on the anterior body of the corpus callosum (particularly the fibers connecting dorsomedial and dorsolateral prefrontal cortex) as well as a tendency for decreased FA in the right cingulum and left anterior limb of the internal capsule.

In the same line, Chiu et al. (2011) tried to overcome some of the inconsistencies in most of DTI studies that have used either a voxel-based morphometry or a region of interest analysis approach, by suggesting the use of diffusion spectrum imaging (DSI) based tractography in which a mapping of the angular distribution of water molecules displacement is obtained by a diffusion tractography approach called tract-specific analysis. The authors calculate the Generalized Fractional Anisotropy (GFA) in two white matter tracts previously associated with OCD - the anterior cingulum bundle and the anterior thalamic radiation. Again, a significant decreased

diffusivity index (mean GFA) was evident in OCD patients in both the right anterior thalamic radiation and the left anterior cingulum bundle.

Bora et al. (2011) moved a step further trying to clarify if white matter abnormalities in OCD were either due to axonal damage or changes in myelination processes. In order to do that, they looked at the FA levels as well as AD (an index of axonal damage) and RD (an index of abnormal myelination) in OCD patients when compared with healthy controls. In terms of FA, a Tract-Based Statistic Analysis showed that the only significant finding was, again, a decrease of FA levels in the body of the corpus callosum for the OCD patients. More interestingly, those differences seemed to be due to an RD increase rather than AD, and thus pointing to abnormal myelination rather than axonal damage.

However, completely different findings were reported by Li et al. (2011) in a study of several white matter indexes (e.g., FA, RD, AD) in a group of OCD patients compared with healthy matched controls. Contrasted with Bora et al. (2011), no areas of decreased FA were reported and increased FA levels were found in right superior frontal gyrus as well as in the corpus callosum. Interestingly, FA increases were associated with increased AD in the same regions. Once again, we are in face of contradictory findings that may be due to the different methods used (e.g., Tract-Based Statistic Analysis in Bore's et al. study).

A recent study by Gonçalves et al. (2015) examined white matter connectivity in the inferior frontal gyrus and its parcelations (pars orbitalis POrb, pars opercularis POper, pars triangularis PTri), as captured by several DTI indices (FA, MD, RD, and AD). They found evidence for significant alterations in brain connectivity for persons with OCD, as expressed by low levels of fractional anisotropy and high levels of diffusivity in the whole IFG as well as its parcelations (the POper, POrb and PTri). Additionally, these alterations seem to impact structural connectivity in the left and right hemispheres. Finally, while differences in RD were widespread through most regions analyzed (except for the IPOrb), higher levels of AD were restricted by region (e.g. the IIFG, IPTri). These alterations suggest the existence of axonal pathology (i.e. increased axial diffusivity) and altered myelination (i.e. increased radial diffusivity) in white matter adjacent to a core brain region implicated in inhibitory control.

Li et al. (2014) used a support vector learning machine method to test the possibility of correctly classify OCD and normal controls based on DTI data from OCD patients and healthy controls. The machine learning algorithm was able to classify individuals with significant levels of accuracy (84%) based on alterations of a

distributed brain network, including: bilateral prefrontal and temporal regions, inferior fronto-occipital fasciculus, superior fronto-parietal fasciculus, splenium of corpus callosum and left middle cingulum bundle. These results suggest that diffusivity abnormalities widespread in the brain are promising markers for OCD.

Trying to put together data from gray matter and white matter DTI alterations, Kim, Jung, Kim, Jang, and Kwon (2015) search for latent covariance patterns of gray and white matter that may contribute to structural alterations in the in MRI and DTI images from OCD patients and healthy controls. The authors confirmed alterations of the interrelated matter networks (gray and white matter) in the occipital and parietal lobes, interhemispheric connections in the frontal lobe and cerebellum.

Several meta-analysis have been trying to pool together some of the major findings exemplified above. For example, Fontenelle et al. (2009) published the first narrative review of brain white matter abnormalities in OCD including morphometric, spectroscopic and DTI studies. In terms of DTI, FA alterations (mostly reductions) were found in different brain regions, particularly, semioval center, corpus callosum, parietal white matter, subinsular white matter, anterior cingulate and internal capsule. Overall, these results are consistent with results reported about morphometric alterations in the corpus callosum, parietal, anterior cingulate and internal capsule. Additionally, diffusion alterations were evident in the semioval center and subinsula white matter. The semioval center is a mass of projection and association white matter fibers underneath the cerebral cortex. Diffusivity alteration in these regions may be associated with problems cortical-subcortical and intercortical connectivity. Subinsular white matter alterations may play a role in interoceptive awareness and emotional processing impairments (e.g., disgust).

A subsequent meta-analysis by Peng et al. (2012), with seven DTI studies, found decreased FA levels in several white matter tracts, namely: cingulum bundle, inferior fronto-occipital fasciculus, and superior longitudinal fasciculus. On the contrary, higher FA was evident in the uncinate fasciculus. As discussed before, the cingulum bundle connects regions from the frontal, temporal, and parietal and may be associated with OCD deficits in executive functioning and emotional regulation. The inferior fronto-occipital fasciculus connects the frontal and occipital lobes and involved in the executive integration of auditory and visual processing (Takeuchi et al., 2013). The superior longitudinal fasciculus connects frontal, parietal, temporal and occipital regions from each hemisphere. This fasciculus has several components and is involved in motor regulation, visual spatial attention, working memory (Kamali, Flanders, Brody, Hunter, &

Hasan, 2014). All these functions have been reported as impaired in OCD. More curious is the increased connectivity in the uncinate fasciculus connecting the anterior temporal lobe with the inferior frontal lobe. In its trajectory, uncinate fasciculus connects amygdala and hippocampus to the insular cortex. Some studies have involved the fasciculus in auto-noetic consciousness (Keenan, Wheeler, Gallup, & Pascual-Leone, 2000) and one can speculate that increased FA in this fasciculus may be associated with OCD tendency for increased self-consciousness (i.e., overawareness of one's thoughts) (J. Koch & Exner, 2015).

A more recent meta-analysis of DTI studies by Piras, Piras, Caltagirone, and Spalletta (2013) confirmed widespread alterations of multiple brain networks, even though in directions not completely consistent with previous analyses. In a systematic review of 15 studies, the authors confirmed a pattern of dissociated connectivity characterized by increased connectivity in several frontal-subcortical pathways (e.g. anterior limb of internal capsule, genu of the corpus callosum, posterior limb of internal capsule, and thalamus) and decreased connectivity in tracks linking frontal, parietal and occipital regions (e.g., cingulum bundle, uncinate fasciculus, inferior fronto-occipital fasciculus, inferior longitudinal fasciculus, superior longitudinal fasciculus). This is the first time the inferior longitudinal fasciculus is reported to be altered in OCD. This is a tract connecting the anterior temporal lobe with the occipital lobe that has been reported as involved in thought disorders, and visual emotional processes (Ashtari, 2012)

Reviewing both voxel and tract-based DTI studies, K. Koch, Reess, Rus, Zimmer, and Zaudig (2014) acknowledge the conflicting findings in current research but point out to the consistent decrease FA in the corpus callosum and in the cingulum bundle and growing evidence of extension of decrease connectivity in parietal and occipital regions, helping explaining the diversity of psychological impairments in OCD.

Radua et al. (2014) in a first multimodal meta-analysis of morphometric and DTI studies confirmed the existence of widespread abnormalities in white matter (e.g., cingulum bundle, corpus callosum, superior longitudinal fasciculus, middle and inferior longitudinal fasciculi, anterior thalamic radiation, internal capsule, frontal aslant tract and/or inferior fronto-occipital fasciculus) particularly by increased volume and decreased FA in the anterior midline tracts (i.e., crossing between the anterior parts of the cingulum bundle and the body of CC).

These results are consistent with a meta-analysis by Eng, Sim, and Chen (2015) combining data from gray matter, white matter and functional studies. The authors

found, in terms of white matter: decreased FA in the right superior longitudinal fasciculus (temporal part), left posterior corona radiate, right posterior thalamic radiation; inferior fronto-occipital fasciculus; inferior longitudinal fasciculus, left putamen; forceps major and minor of the corpus callosum. On the contrary, increased FA values were found in: right frontal and medial frontal gyrus, body of the corpus callosum; forceps minor; anterior thalamic radiate; right superior longitudinal fasciculus (near inferior parietal lobule). The FA decrease in the corona radiate deserves a comment. Corona radiate is a set of fibers projecting from and to the cortex and includes, among others, the corticospinal tract, and is involved in motor functions.

Overall, the studies reported above are suggestive of structural connectivity abnormalities that are widely spread in the brain. Diffusions abnormalities (independent of the direction) were found in several major projection, association and commissural tracts: (1) superior longitudinal fasciculus (thought to play a role in motor regulation, visual attention and working memory); (2) the inferior fronto-occipital fasciculus (associated with executive functioning, particularly the integration of perceptual processes); (3) inferior longitudinal fasciculus (related with visual and emotional processing); (4) cingulum bundle (important role in inhibitory control and emotional regulation); (5) semioval center (cortical-subcortical and intracortical regulation); (6) internal capsule (associated with inhibitory control); (7) different regions of the corpus callosum (associated with emotional, cognitive and perceptual regulation); (8) thalamic radiation (possible association with the integration of cognitive, emotional and sensory regulation); (9) optic radiation (a core role in visual processing); (10) uncinate fasciculus (possible associations with increased self-consciousness). Additional diffusion abnormalities were reported in white matter adjacent to some gray matter structures: (1) superior frontal gyrus (core role in working memory); (2) medial frontal gyrus (possible associations with emotional regulation); (3) inferior frontal gyrus (playing an important role in inhibitory control); (4) caudate (role in cognitive flexibility and working memory); (5) insulate cortex (emotional processing); (6) parietal cortex (possibly associated with visual spatial processing); (7) thalamus (possible associations with inhibitory control deficits), (8) supramarginal and lingual gyri (associated with visual processing and emotional processing).

White Matter in Different OCD Cohorts

As we have been seeing, despite some consensus in white matter morphometric and connectivity abnormalities in white matter, the direction of these

changes is still very inconsistent. Part of this is due to the different methods that have been used across different studies and problems associated with the technique such as: technical problems associated with different fiber-crossing in distinct regions, diversity of signal estimation methods, and dissimilar algorithms used in fiber tracking (Liu et al., 2015).

Inconsistencies may also be product of the heterogeneity of OCD endophenotypes (Taylor, 2012). Therefore, there is a possibility that the white matter abnormalities exhibited by OCD patients have a genetic basis. A DTI study by Den Braber et al. (2011) compared both FA and white matter volumes (VBM approach) in concordant and discordant monozygotic twins scoring high and low on OCD. More specifically the following hypotheses were tested: (1) environmental risk hypothesis -testing the FA and volumetric differences in high versus low scoring twins from discordant pairs; (2) genetic risk hypothesis - testing the FA and volumetric differences in concordant high when compared with concordant low-scoring twins. In terms of the environmental risk hypotheses the authors found that twins scoring high on OCD symptoms when compared with their low scoring pairs have significantly increased FA levels in the right orbitofrontal, left dorsolateral prefrontal, left precentral, left corpus callosum, left cingulate, left insula, right superior parietal, right temporal and bilaterally in cerebellar regions as well as evidence for decreased FA levels in other brain regions: bilaterally medial frontal and temporal regions, right insula, left parietal, and right occipital, regions and left brainstem/pons. The white matter volumetric analysis confirmed a significantly increase in the left dorsolateral prefrontal cortex and decrease in the right medial frontal and left parietal regions. In terms of the genetic risk hypothesis the authors found that comparing concordant high-scoring twins with low-scoring ones there were increased FA levels in the right medial frontal, right temporal and bilateral parietal and decreased FA in the left inferior frontal lobe. Additionally, in terms of white matter volumetry, a significant decrease was found in the left inferior frontal lobe in the high-scoring concordant twins when compared with the low scoring. Overall the results from this study point to the fact that changes in white matter structures are associated with different types of risk, with the genetic versus environmental risks cohorts affecting the brain in different ways. This fact may help explaining the inconsistency in finding derived from previous studies and calls for the need for differentiating endophenotypes in OCD research.

However, other characteristics of the OCD population (other than genetic versus environmental risk) may contribute to the confounding findings presented so far.

For example, a study by Benedetti et al. (2013) using TBSS for comparing FA, RD and AD in a sample of drug naïve OCD when compared with medicated, was able to find evidence of decreased widespread FA levels and increased MD and RD, but only in medicated OCD patients. This data may indicate medication as a potential confounding factor in most of the studies reported above. While authors interpreted the findings as possible evidence of the effects of medication in the white matter microstructure a, possible and equally plausible hypothesis, is that these results may be associated with OCD severity.

Qing Fan et al. (2012) looking at several diffusion indexes in unmedicated OCD patients and healthy controls were able to find increased RD in several brain regions (e.g., left medial superior frontal gyrus, temporoparietal lobe, occipital lobe, striatum, insula and right midbrain) but also that some of these regions were responsive to the effects of medication by decreasing RD levels (e.g., left striatum and right midbrain). More recently, S. Fan et al. (2016) comparing white matter changes in un-medicated OCD patients, their unaffected siblings, and healthy controls, showed decreased FA in the left cingulate bundle in the un-medicated OCD group, as compared to healthy controls. Despite not statistically significant, the OCD unaffected siblings also exhibited decreased FA as compared to the healthy control group.

K. Koch et al. (2012) tried to correlate alteration in white matter diffusivity and patterns of symptomatic configuration (checking, washing, ordering, hoarding, obsessing and neutralizing) in OCD patients. Two main results are worth mention here. First, the obsessing dimension was found to be negatively associated with FA levels in the corpus callosum and the cingulate bundle. Second, and most interestingly, patients scoring high in ordering tend to have decreased FA levels in areas associated with visual processing, such as the right inferior fronto-occipital fasciculus and the right optic radiation.

Also, in what was the first multimodal study combining DTI (FA and ADC) with magnetic transfer imaging (MTI - ratio between free mobile protons and immobile protons), Glahn, Prell, Grosskreutz, Peschel, and Müller-Vahl (2015) analyzed both gray and white matter indexes in OCD patients and healthy controls. The authors found evidence of significant negative correlations between the ADC maps in the white matter of the left cingulate cortex

and compulsion scores in the Y-BOCS. No significant correlations were found between ADC and obsessions. Scores of obsessions correlated significantly with the left inferior parietal lobe MRT maps.

Altogether, research shows that white matter abnormalities may be associated with: (1) type of risk (genetic versus environmental); (2) medication history; (3) type of OCD; and severity of OCD symptoms.

Conclusion

There is now evidence for widespread white matter morphometric and connectivity abnormalities affecting major white matter tracts: superior longitudinal fasciculus; inferior fronto-occipital fasciculus; inferior longitudinal fasciculus; cingulum bundle; semioval center; internal capsule; different regions of the corpus callosum; thalamic radiation; uncinate fasciculus and optic radiation. Despite some contradictory findings, probably due to different methods and the heterogeneity of OCD cohorts, these evidences are consistent with gray matter studies. Additionally, white matter in regions adjacent to gray matter structures were also shown to exhibit morphometric and/or connectivity abnormalities, such as: superior frontal gyrus; dorsolateral prefrontal medial frontal gyrus; inferior frontal gyrus; caudate; insulate cortex; parietal cortex; supramarginal and lingual gyri; and thalamus.

Figure 1 presents the possible association between white matter alterations and OCD major psychological impairments. While trying to be as comprehensive as possible it is important to remark that, mainly when it comes to white matter tracts, several psychological processes are involved and each track can play an important role in several psychological processes and OCD symptoms.

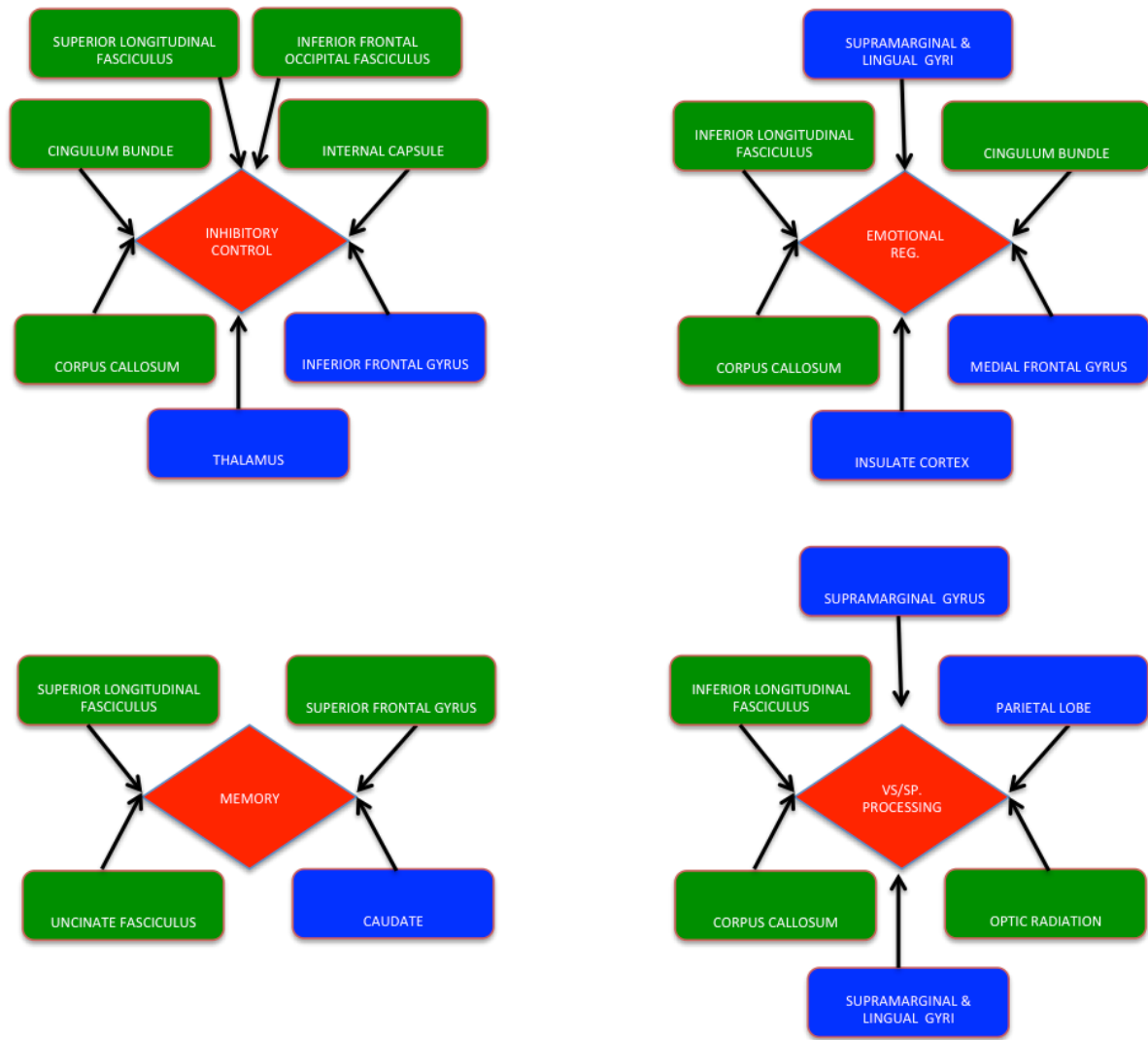


Figure 1. Relationship between white matter alterations and OCD major psychological features (green - white matter tracts; blue - white matter adjacent to gray matter structures; red - psychological dimensions)

Despite the increase understanding brought by ever-more-sophisticated methods for white matter imaging, the present conclusions are still limited by methodological constrains associated with different techniques and algorithms as well as characteristics and heterogeneity among the selected OCD cohorts.

Conflict of interest and financial disclosure

The authors followed the International Committee or Journal of Medical Journals Editors (ICMJE) form for disclosure of potential conflicts of interest. All listed authors concur with the submission of the manuscript, the final version has been approved by all authors. The authors have no financial or personal conflicts of interest. The first author was funded by the Brazilian National Council for Scientific and Technological Development (CNPq) as a Special Visiting Researcher of the Science Without Borders program (grant number: 401143/2014-7). This study was partially conducted at the Neuropsychophysiology Lab from the Psychology Research Centre (UID/PSI/01662/2013), University of Minho, and supported by the Portuguese Foundation for Science and Technology and the Portuguese Ministry of Science, Technology and Higher Education through national funds and co-financed by FEDER through

COMPETE2020 under the PT2020 Partnership Agreement (POCI-01-0145-FEDER-007653).

References

- Alexander, A. L., Lee, J. E., Lazar, M., & Field, A. S. (2007). Diffusion tensor imaging of the brain. *Neurotherapeutics : The Journal of the American Society for Experimental NeuroTherapeutics*, 4(3), 316-29. <http://doi.org/10.1016/j.nurt.2007.05.011>
- Ashtari, M. (2012). Anatomy and functional role of the inferior longitudinal fasciculus: a search that has just begun. *Developmental Medicine and Child Neurology*, 54(1), 6-7. <http://doi.org/10.1111/j.1469-8749.2011.04122.x>
- Benedetti, F., Giacosa, C., Radaelli, D., Poletti, S., Pozzi, E., Dallaspezia, S., ... Smeraldi, E. (2013). Widespread changes of white matter microstructure in obsessive-compulsive disorder: effect of drug status. *European Neuropsychopharmacology*, 23(7), 581-93. <http://doi.org/10.1016/j.euroneuro.2012.07.002>
- Bora, E., Harrison, B. J., Fornito, A., Cocchi, L., Pujol, J., Fontenelle, L. F., ... Yücel, M. (2011). White matter microstructure in patients with obsessive-compulsive disorder. *Journal of Psychiatry & Neuroscience : JPN*, 36(1), 42-6. <http://doi.org/10.1503/jpn.100082>
- Cannistraro, P. A., Makris, N., Howard, J. D., Wedig, M. M., Hodge, S. M., Wilhelm, S., ... Rauch, S. L. (2007). A diffusion tensor imaging study of white matter in obsessive-compulsive disorder. *Depression and Anxiety*, 24(6), 440-6. <http://doi.org/10.1002/da.20246>
- Chen, J., Silk, T., Seal, M., Dally, K., & Vance, A. (2013). Widespread decreased grey and white matter in paediatric obsessive-compulsive disorder (OCD): a voxel-based morphometric MRI study. *Psychiatry*

- Research, 213(1), 11-7. <http://doi.org/10.1016/j.psychres.2013.02.003>
- Chiu, C.-H., Lo, Y.-C., Tang, H.-S., Liu, I.-C., Chiang, W.-Y., Yeh, F.-C., ... Tseng, W.-Y. I. (2011). White matter abnormalities of fronto-striato-thalamic circuitry in obsessive-compulsive disorder: A study using diffusion spectrum imaging tractography. *Psychiatry Research*, 192(3), 176-82. <http://doi.org/10.1016/j.psychres.2010.09.009>
- Chon, M. W., Choi, J. S., Kang, D. H., Jung, M. H., & Kwon, J. S. (2010). MRI study of the cavum septum pellucidum in obsessive-compulsive disorder. *European Archives of Psychiatry and Clinical Neuroscience*, 260(4), 337-343. <http://doi.org/10.1007/s00406-009-0081-6>
- de Wit, S. J., Alonso, P., Schwenen, L., Mataix-Cols, D., Lochner, C., Menchón, J. M., ... van den Heuvel, O. A. (2014). Multicenter voxel-based morphometry mega-analysis of structural brain scans in obsessive-compulsive disorder. *The American Journal of Psychiatry*, 171(3), 340-9. <http://doi.org/10.1176/appi.ajp.2013.13040574>
- Den Braber, A., Van 't Ent, D., Boomsma, D. I., Cath, D. C., Veltman, D. J., Thompson, P. M., & De Geus, E. J. C. (2011). White matter differences in monozygotic twins discordant or concordant for obsessive-compulsive symptoms: A combined diffusion tensor imaging/voxel-based morphometry study. *Biological Psychiatry*, 70(10), 969-977. <http://doi.org/10.1016/j.biopsych.2011.03.029>
- Di Paola, M., Luders, E., Rubino, I. A., Siracusano, A., Manfredi, G., Girardi, P., ... Spalletta, G. (2013). The structure of the corpus callosum in obsessive compulsive disorder. *European Psychiatry : The Journal of the Association of European Psychiatrists*, 28(8), 499-506. <http://doi.org/10.1016/j.eurpsy.2012.07.001>
- Duran, F. L. de S., Hoexter, M. Q., Valente, A. A., Miguel, E. C., & Busatto, G. F. (2009). Association between symptom severity and internal capsule volume in obsessive-compulsive disorder. *Neuroscience Letters*, 452(1), 68-71. <http://doi.org/10.1016/j.neulet.2009.01.007>
- Eng, G. K., Sim, K., & Chen, S.-H. A. (2015). Meta-analytic investigations of structural grey matter, executive domain-related functional activations, and white matter diffusivity in obsessive compulsive disorder: an integrative review. *Neuroscience and Biobehavioral Reviews*, 52, 233-57. <http://doi.org/10.1016/j.neubiorev.2015.03.002>
- Fan, Q., Yan, X., Wang, J., Chen, Y., Wang, X., Li, C., ... Xiao, Z. (2012). Abnormalities of white matter microstructure in unmedicated obsessive-compulsive disorder and changes after medication. *PLoS One*, 7(4), e35889. <http://doi.org/10.1371/journal.pone.0035889>
- Fan, S., van den Heuvel, O. A., Cath, D. C., van der Werf, Y. D., de Wit, S. J., de Vries, F. E., ... Pouwels, P. J. W. (2016). Mild White Matter Changes in Un-medicated Obsessive-Compulsive Disorder Patients and Their Unaffected Siblings. *Frontiers in Neuroscience*, 9, 495. <http://doi.org/10.3389/fnins.2015.00495>
- Fontenelle, L. F., Harrison, B. J., Yücel, M., Pujol, J., Fujiwara, H., & Pantelis, C. (2009). Is there evidence of brain white-matter abnormalities in obsessive-compulsive disorder?: a narrative review. *Topics in Magnetic Resonance Imaging*, 20(5), 291-8. <http://doi.org/10.1097/RMR.0b013e3181e8f22c>
- Garibotto, V., Scifo, P., Gorini, A., Alonso, C. R., Brambati, S., Bellodi, L., & Perani, D. (2010). Disorganization of anatomical connectivity in obsessive compulsive disorder: a multi-parameter diffusion tensor imaging study in a subpopulation of patients. *Neurobiology of Disease*, 37(2), 468-76. <http://doi.org/10.1016/j.nbd.2009.11.003>
- Glahn, A., Prell, T., Grossekreutz, J., Peschel, T., & Müller-Vahl, K. R. (2015). Obsessive-compulsive disorder is a heterogeneous disorder: evidence from diffusion tensor imaging and magnetization transfer imaging. *BMC Psychiatry*, 15(1), 135. <http://doi.org/10.1186/s12888-015-0535-5>
- Gonçalves, O. F., Soares, J. M., Carvalho, S., Leite, J., Ganho, A., Fernandes-Gonçalves, A., ... Sampaio, A. (2015). Brain activation of the defensive and appetitive survival systems in obsessive compulsive disorder. *Brain Imaging and Behavior*, 9(2), 255-63. <http://doi.org/10.1007/s11682-014-9303-2>
- Gonçalves, Ó. F., Sousa, S., Maia, L., Carvalho, S., Leite, J., Ganho, A., ... Sampaio, A. (2015). Inferior frontal gyrus white matter abnormalities in obsessive-compulsive disorder. *NeuroReport*, 26(9), 595-500. <http://doi.org/10.1097/WNR.0000000000000377>
- Heilbronner, S. R., & Haber, S. N. (2014). Frontal Cortical and Subcortical Projections Provide a Basis for Segmenting the Cingulum Bundle: Implications for Neuroimaging and Psychiatric Disorders. *Journal of Neuroscience*, 34(30), 10041-10054. <http://doi.org/10.1523/JNEUROSCI.5459-13.2014>
- Hosseinzadeh, K., Luo, J., Borhani, a, & Hill, L. (2013). Non-visualisation of cavum septi pellucidi: implication in prenatal diagnosis? *Insights into Imaging*, 4(3), 357-67. <http://doi.org/10.1007/s13244-013-0244-x>
- Jaafari, N., Frasca, M., Rigalleau, F., Rachid, F., Gil, R., Oli??, J. P., ... Vibert, N. (2013). Forgetting what you have checked: A link between working memory impairment and checking behaviors in obsessive-compulsive disorder. *European Psychiatry*, 28(2), 87-93. <http://doi.org/10.1016/j.eurpsy.2011.07.001>
- Jose, D., Narayanaswamy, J. C., Agarwal, S. M., Kalmady, S. V., Venkatasubramanian, G., & Reddy, Y. C. J. (2015). Corpus callosum abnormalities in medication-naïve adult patients with obsessive compulsive disorder. *Psychiatry Research*, 231(3), 341-5. <http://doi.org/10.1016/j.psychres.2015.01.019>
- Kamali, A., Flanders, A. E., Brody, J., Hunter, J. V., & Hasan, K. M. (2014). Tracing superior longitudinal fasciculus connectivity in the human brain using high resolution diffusion tensor tractography. *Brain Structure & Function*, 219(1), 269-81. <http://doi.org/10.1007/s00429-012-0498-y>
- Keenan, J. P., Wheeler, M. A., Gallup, G. G., & Pascual-Leone, A. (2000). Self-recognition and the right prefrontal cortex. *Trends in Cognitive Sciences*, 4(9), 338-344. [http://doi.org/10.1016/S1364-6613\(00\)01521-7](http://doi.org/10.1016/S1364-6613(00)01521-7)
- Kim, S. N., Lee, T. Y., Yoon, Y. B., & Kwon, J. S. (2016). Neurocognitive deficit in first-episode, drug-naïve obsessive-compulsive disorder. S.N. Kim, T.Y. Lee, Y.B. Yoon, J.S. Kwon. 2016. EW19. *European Psychiatry* 33 (Supplement): S122-S123, Supplement(33), S122-S123. <http://doi.org/10.1016/j.eurpsy.2016.01.137>
- Kim, S.-G., Jung, W. H., Kim, S. N., Jang, J. H., & Kwon, J. S. (2015). Alterations of Gray and White Matter Networks in Patients with Obsessive-Compulsive Disorder: A Multimodal Fusion Analysis of Structural MRI and DTI Using mCCA+jICA. *PLoS One*, 10(6), e0127118. <http://doi.org/10.1371/journal.pone.0127118>
- Koch, J., & Exner, C. (2015). Selective attention deficits in obsessive-compulsive disorder: the role of metacognitive processes. *Psychiatry Research*, 225(3), 550-5. <http://doi.org/10.1016/j.psychres.2014.11.049>
- Koch, K., Reess, T. J., Rus, O. G., Zimmer, C., & Zaudig, M. (2014). Diffusion tensor imaging (DTI) studies in patients with obsessive-compulsive disorder (OCD): a review. *Journal of Psychiatric Research*, 54, 26-35. <http://doi.org/10.1016/j.jpsychires.2014.03.006>
- Koch, K., Wagner, G., Schachtzabel, C., Christoph Schultz, C., Straube, T., Güllmar, D., ... Schlösser, R. G. M. (2012). White matter structure and symptom dimensions in obsessive-compulsive disorder. *Journal of Psychiatric Research*, 46(2), 264-270. <http://doi.org/10.1016/j.jpsychires.2011.10.016>
- Kwon, J. S., Shenton, M. E., Hirayasu, Y., Salisbury, D. F., Fischer, I. A., Dickey, C. C., ... McCarley, R. W. (1998). MRI study of cavum septi pellucidi in schizophrenia, affective disorder, and schizotypal personality disorder. *The American Journal of Psychiatry*, 155(4), 509-15. <http://doi.org/10.1176/ajp.155.4.509>
- Li, F., Huang, X., Tang, W., Yang, Y., Li, B., Kemp, G. J., ... Gong, Q. (2014). Multivariate pattern analysis of DTI reveals differential white matter in individuals with obsessive-compulsive disorder. *Human Brain Mapping*, 35(6), 2643-51. <http://doi.org/10.1002/hbm.22357>
- Li, F., Huang, X., Yang, Y., Li, B., Wu, Q., Zhang, T., ... Gong, Q. (2011). Microstructural brain abnormalities in patients with obsessive-compulsive disorder: diffusion-tensor MR imaging study at 3.0 T. *Radiology*, 260(1), 216-23. <http://doi.org/10.1148/radiol.11101971>
- Liu, S., Cai, W., Liu, S., Zhang, F., Fulham, M., Feng, D., ... Kikinis, R. (2015). Multimodal neuroimaging computing: a review of the applications in neuropsychiatric disorders. *Brain Informatics*, 2, 167-180. <http://doi.org/10.1007/s40708-015-0019-x>
- Lochner, C., Fouché, J.-P., du Plessis, S., Spottiswoode, B., Seedat, S., Fineberg, N., ... Stein, D. J. (2012). Evidence for fractional anisotropy and mean diffusivity white matter abnormalities in the internal capsule and cingulum in patients with obsessive-compulsive disorder. *Journal of Psychiatry & Neuroscience : JPN*, 37(3), 193-9. <http://doi.org/10.1503/jpn.110059>
- Lopez, K. C., Lalonde, F., Mattai, A., Wade, B., Clasen, L., Rapoport, J., & Giedd, J. N. (2013). Quantitative morphology of the corpus callosum in obsessive-compulsive disorder. *Psychiatry Research -*

- Neuroimaging, 212(1), 1-6.
<http://doi.org/10.1016/j.psychresns.2012.10.012>
- Menzies, L., Williams, G. B., Chamberlain, S. R., Ooi, C., Fineberg, N., Suckling, J., ... Bullmore, E. T. (2008). White matter abnormalities in patients with obsessive-compulsive disorder and their first-degree relatives. *The American Journal of Psychiatry*, 165(10), 1308-15. <http://doi.org/10.1176/appi.ajp.2008.07101677>
- Nakamae, T., Narumoto, J., Sakai, Y., Nishida, S., Yamada, K., Nishimura, T., & Fukui, K. (2011). Diffusion tensor imaging and tract-based spatial statistics in obsessive-compulsive disorder. *Journal of Psychiatric Research*, 45(5), 687-90. <http://doi.org/10.1016/j.jpsychires.2010.09.016>
- Nakamae, T., Narumoto, J., Shibata, K., Matsumoto, R., Kitabayashi, Y., Yoshida, T., ... Fukui, K. (2008). Alteration of fractional anisotropy and apparent diffusion coefficient in obsessive-compulsive disorder: a diffusion tensor imaging study. *Progress in Neuro-Psychopharmacology & Biological Psychiatry*, 32(5), 1221-6. <http://doi.org/10.1016/j.pnpb.2008.03.010>
- Oh, J. S., Jang, J. H., Jung, W. H., Kang, D.-H., Choi, J.-S., Choi, C.-H., ... Kwon, J. S. (2012). Reduced fronto-callosal fiber integrity in unmedicated OCD patients: a diffusion tractography study. *Human Brain Mapping*, 33(10), 2441-52. <http://doi.org/10.1002/hbm.21372>
- Park, H. Y., Park, J. S., Kim, S. H., Jang, J. H., Jung, W. H., Choi, J. S., ... Kwon, J. S. (2011). Midsagittal structural differences and sexual dimorphism of the corpus callosum in obsessive-compulsive disorder. *Psychiatry Research - Neuroimaging*, 192(3), 147-153. <http://doi.org/10.1016/j.psychresns.2010.12.003>
- Park, S.-E., & Jeong, G.-W. (2015). Cerebral white matter volume changes in patients with obsessive-compulsive disorder: Voxel-based morphometry. *Psychiatry and Clinical Neurosciences*, 69(11), 717-23. <http://doi.org/10.1111/pcn.12317>
- Peng, Z., Lui, S. S. Y., Cheung, E. F. C., Jin, Z., Miao, G. D., Jing, J., & Chan, R. C. K. (2012). Brain structural abnormalities in obsessive-compulsive disorder: Converging evidence from white matter and grey matter. *Asian Journal of Psychiatry*, 5(4), 290-296. <http://doi.org/10.1016/j.ajp.2012.07.004>
- Piras, F., Piras, F., Caltagirone, C., & Spalletta, G. (2013). Brain circuitries of obsessive compulsive disorder: a systematic review and meta-analysis of diffusion tensor imaging studies. *Neuroscience and Biobehavioral Reviews*, 37(10 Pt 2), 2856-77. <http://doi.org/10.1016/j.neubiorev.2013.10.008>
- Piras, F., Piras, F., Chiapponi, C., Girardi, P., Caltagirone, C., & Spalletta, G. (2015). Widespread structural brain changes in OCD: a systematic review of voxel-based morphometry studies. *Cortex*, 62, 89-108. <http://doi.org/10.1016/j.cortex.2013.01.016>
- Radua, J., Grau, M., van den Heuvel, O. A., Thiebaut de Schotten, M., Stein, D. J., Canales-Rodríguez, E. J., ... Mataix-Cols, D. (2014). Multimodal voxel-based meta-analysis of white matter abnormalities in obsessive-compulsive disorder. *Neuropsychopharmacology*, 39(7), 1547-57. <http://doi.org/10.1038/npp.2014.5>
- Saito, Y., Nobuhara, K., Okugawa, G., Takase, K., Sugimoto, T., Horiuchi, M., ... Kinoshita, T. (2008). Corpus callosum in patients with obsessive-compulsive disorder: diffusion-tensor imaging study. *Radiology*, 246(2), 536-42. <http://doi.org/10.1148/radiol.2462061469>
- Smith, S. M., Jenkinson, M., Johansen-Berg, H., Rueckert, D., Nichols, T. E., Mackay, C. E., ... Behrens, T. E. J. (2006). Tract-based spatial statistics: voxelwise analysis of multi-subject diffusion data. *NeuroImage*, 31(4), 1487-505. <http://doi.org/10.1016/j.neuroimage.2006.02.024>
- Snyder, H. R., Kaiser, R. H., Warren, S. L., & Heller, W. (2015). Obsessive-compulsive disorder is associated with broad impairments in executive function: A meta-analysis. *Clinical Psychological Science*, 3(2), 301-330. <http://doi.org/10.1177/2167702614534210>
- Sullivan, E. V., Zahr, N. M., Rohlfing, T., & Pfefferbaum, A. (2010). Fiber tracking functionally distinct components of the internal capsule. *Neuropsychologia*, 48(14), 4155-4163. <http://doi.org/10.1016/j.neuropsychologia.2010.10.023>
- Szeszko, P. R., Ardekani, B. A., Ashtari, M., Malhotra, A. K., Robinson, D. G., Bilder, R. M., & Lim, K. O. (2005). White matter abnormalities in obsessive-compulsive disorder: a diffusion tensor imaging study. *Archives of General Psychiatry*, 62(7), 782-90. <http://doi.org/10.1001/archpsyc.62.7.782>
- Takeuchi, H., Taki, Y., Sassa, Y., Hashizume, H., Sekiguchi, A., Fukushima, A., & Kawashima, R. (2013). Brain structures associated with executive functions during everyday events in a non-clinical sample. *Brain Structure & Function*, 218(4), 1017-32. <http://doi.org/10.1007/s00429-012-0444-z>
- Taylor, S. (2012). Endophenotypes of obsessive-compulsive disorder: Current status and future directions. *Journal of Obsessive-Compulsive and Related Disorders*, 1(4), 258-262. <http://doi.org/10.1016/j.jocrd.2012.06.004>
- Yoo, S. Y., Jang, J. H., Shin, Y.-W., Kim, D. J., Park, H.-J., Moon, W.-J., ... Kwon, J. S. (2007). White matter abnormalities in drug-naïve patients with obsessive-compulsive disorder: a diffusion tensor study before and after citalopram treatment. *Acta Psychiatrica Scandinavica*, 116(3), 211-9. <http://doi.org/10.1111/j.1600-0447.2007.01046.x>